

Automatic Detection of Follicles in Ultrasound Images of Ovaries using Edge based Method

Pratyush Singh¹ and Manjunath AE²

¹Department of Computer Science and Engineering, R.V. College of Engineering, Bengaluru, Karnataka, India

²Professor, Department of Computer Science and Engineering, R.V. College of Engineering, Bengaluru, Karnataka, India

Abstract - The ovarian ultrasound imaging is an effective tool in infertility treatment. Monitoring the follicles is especially important in human reproduction. Periodic measurements of the size and shape of follicles over several days are the primary means of evaluation by physicians. Today monitoring the follicles is done by non-automatic means with human interaction. This work can be very demanding and inaccurate and, in most of the cases, means only an additional burden for medical experts. In this paper, a new algorithm for automatic detection of follicles in ultrasound images of ovaries is proposed. It has typical object recognition scheme (preprocessing, segmentation, feature extraction and classification). The proposed algorithm uses edge based method for segmentation. The preprocessing employs gaussian low pass filter or contourlet transform for despeckling the ultrasound images of ovaries. The classification is based on 4σ intervals around the mean feature (geometric) values. The experimentation has been done using sample ultrasound images of ovaries and the results are compared with the inferences drawn by medical expert. The experimental results demonstrate the efficiency of the method.

Key Words: Ultrasound Image, Ovarian follicle segmentation, Edge based method, Gaussian low pass filter, Contourlet transform

1. INTRODUCTION

The ovarian follicles are spherical fluid filled structures. The outcome of pregnancy is dependent upon the quality of the female gamete oocyte contained in the dominant follicle. During the follicular phase, a small cohort of follicles begins to develop. The dominant follicles are those that grow and have potential to ovulate at the end of follicular phase. One member of this group is physiologically selected to ovulate and is the one that exhibit greatly increased hormonal activity causing its growth. The others, lacking hormonal support, undergo atresia.

A complete understanding of ovarian follicle (i.e., a sac containing ova) dynamics is crucial in the field of genetic engineering and human reproduction. For women undergoing assisted reproductive therapy, the ovarian ultrasound imaging has become an effective tool in infertility management. Periodic measurements of the

follicles size over several days are the primary means of evaluation by the physicians. Accurate folliculometry is essential for safe and effective infertility treatment. Here, the main task is to successfully characterize dominant follicles (i.e., the follicles that grow and have potential to ovulate at the end of the follicular phase) from the set of follicles inside the ovary. Not all dominant follicles ovulate and of those that do, not all are of sufficiently high quality to result in pregnancy. To characterize successful dominant follicles, the follicles must be compared with unsuccessful dominant and subdominant follicles and their interactions examined. Follicles can be monitored in several different ways [3]. The best way of monitoring is by using non-invasive methods, e.g. ultrasonography.

With frames of the ovary, grabbed on either way and with appropriate criteria (right shape, antral edge quality, size and echogenity), the follicles (and also their type) can be identified and required analysis accomplished [3]. Today, the monitoring of the follicles is done in a non-automatic way, with human interaction. A doctor normally examine over 30 women a day during their entire cycle (measure every follicle inside the ovary by hand) in order to obtain credible results. This work can be very demanding and inaccurate. An automated computer based method is desirable because of tedious and time consuming nature of manual follicle segmentation.

The literature on computer assisted approaches to the follicle image analysis is scarce. Potocnik and Zazula [4] segmented follicular ultrasound images based on an optimal thresholding applied to coarsely estimated ovary. However, this fully automated method, using the edges for estimation of ovary boundaries and thresholding as a segmentation method, doesnot give optimal results. In [6], this method was upgraded using active contours and consequently, the quality of recognized follicles was considerably improved. Edges of recognized objects were much closer to the real follicle boundaries. However, the question that remains unsolved is how to determine the suitable parameters for snakes automatically. Cigale and Zazula [11] utilize cellular automata and cellular neural networks for the follicle segmentation. The obtained results are very promising but an obvious drawback of these two methods is the difficulty in determination of the required parameters for follicle segmentation. Sarty et al [10] reported a semiautomated

method for the outer follicle wall segmentation, where a frequent manual tracing of the inner border of all follicles is done, using watershed segmentation technique. Watershed segmentation was applied on smoothed image data, which merged some small adjacent follicles. Therefore, binary mathematical morphology was applied to separate such areas.

The edge based segmentation method with Gaussian low pass filter for noise removal has been employed by Hiremath and Tegnour [12] for follicle detection. Due to speckle noise, finding the object boundaries is difficult and thus leads to poor segmentation. Further, a new improved algorithm is proposed in which follicle segmentation is achieved by using a speckle reduction method based on the contourlet transform [14] in preprocessing phase and edge based method for segmentation phase [18]. The experimental results of proposed method are compared with the manual results by medical expert.

The paper is organized as follows. In the section 2, the proposed method for automated detection of follicles in ultrasound images of ovaries is described. In the section 3, the experimental results are presented. The section 4 concludes the paper.

2. PROPOSED METHOD

The block diagram of proposed algorithm for automatic detection of the follicles in an ultrasound image of ovary is shown in Fig.1. In a typical ultrasound image of ovary, there can be found the ovary with the follicles in it, endometrium, blood vessels and added noise due to ultrasound device. Our aim is to locate the follicles in this original image with such a procedure that will step by step reduce the data to be processed. A sample ultrasound image of ovary is shown in the Fig.2. Ovarian follicles are spherical fluid- filled structures [7]. They grow from 8 to 10 on an average. Only the dominant follicle can reach as much as 17 to 25 mm in diameter [5, 10]. The small follicles of 2 to 3 mm can also be perceived in the ultrasound images of ovaries. In the middle of the ovary, other structures can also be found, such as blood vessels, lymphatic glands [5]. Ultrasound ovary images show planar sections through the follicles. These images are characterized by specular reflections and edge information, which is weak and discontinuous. Therefore, traditional edge detection techniques (e.g. Sobel, Prewitt) are susceptible to spurious responses when applied to ultrasound imagery [1]. The main reason, that the follicle segmentation using solely edge information is rather unsuccessful, is a high level of added speckle noise. The follicles being fluid- filled sacs appear as dark oval regions because they display similar fluid echotextures, which are more or less darker than their neighborhood. The follicles could therefore be treated as homogeneous dark regions.

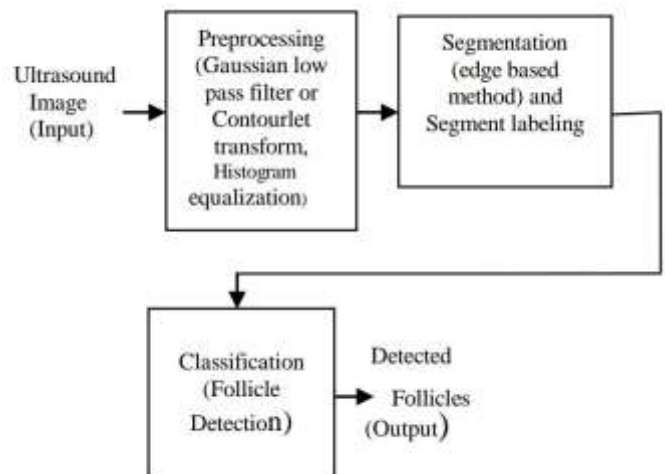


Fig.1 Block diagram of the proposed algorithm.

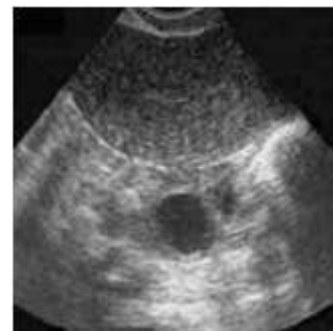

Fig.2 Ultrasound image of ovary with follicles

2.1. Preprocessing Phase

The first step is denoising the image, since ultrasound images are invariably noisy due to the mode of the image acquisition itself. (eg. head of the ultrasound device is not moist enough). Especially, a disturbing type of noise is the speckle noise. We use

- (i) Gaussian low pass filter, or
- (ii) Contourlet transform, for denoising the medical ultrasound images. Then histogram equalization is applied to the filtered image.

2.2. Segmentation Stage

The image after histogram equalization will be the input image for segmentation process. In the segmentation stage, we apply canny operator to the histogram equalized image, for edge detection. In this phase, we have experimented with the other edge detecting operators such as, sobel and prewitt, but canny operator has yielded most satisfying results among all the operators. The resulting edges are broken due to the noise. So these broken edges are filled by using morphological dilation with appropriate structuring element, which yields the segmented image, that contains segmented regions in it. Any spurious regions due to noise are eliminated by morphological erosion. The regions in segmented image having smaller area than the threshold T

are removed. The regions are labeled (identified) and possible holes inside them are filled. Any region touching the borders are removed.

2.3. Feature Extraction

The ovarian follicles are oval shaped compact structures, which resemble the ellipse and are, thus, characterized by the geometric features, namely, majoraxislength, minoraxislength, ratio of majoraxislength to minoraxislength. The ratio of majoraxislength to minoraxislength of the follicle is a useful region descriptor for the follicle regions. Therefore, for classification, we use geometrical feature, namely, the ratio R of major axis length to minor axis length of the follicle regions.

2.4. Classification stage

2.4.1. Training Phase

During training phase, we compute the geometrical feature, namely, the ratio R of majoraxislength to minoraxislength for regions known to be follicles in the training images in consultation with the medical expert. Then, we compute the

sample mean \bar{R} and standard deviation σR of the ratio R, which forms the knowledge base of the follicles. It is experimentally found that $\bar{R} = 1.8427$ and $\sigma R = 0.5971$. It is used for formulating the classification rule for follicle detection in ultrasound images of ovaries as following:

A region with ratio R, is classified as a follicle, if the following condition is satisfied:

$$\bar{R} - \alpha\sigma R < R < \bar{R} + \alpha\sigma R$$

The constant α is empirically determined. In our experiments, it is $\alpha = 4$.

2.4.2. Testing Phase

During the testing phase, we compute the ratio R for a region of the segmented image and apply the 4σ interval based classification rule to determine whether it is a follicle or not.

3. EXPERIMENTAL RESULTS

The experimentation is done using the 50 sample ultrasound images of ovaries (Fig.4), out of which 25 images are used for training phase and other 25 images are used for testing phase. The proposed method has been implemented on the Intel Dual core system with 2GB RAM and 2.77 GHz with Matlab 7.9. The experimental results corresponding to both the methods, namely ,

(i) Method 1- The proposed algorithm with the preprocessing based on gaussian low pass filter, and (ii)

Method 2 – The proposed algorithm with the preprocessing based on contourlet transform, have been analyzed.

The Fig.3 depicts the experimental results for the proposed Method 1. The Fig.3(a) shows an original ultrasound image of the ovary. Initially, the image is processed with Gaussian low pass filter yielding despeckled image. The size of the neighbourhood region is 7x7 pixels with empirical sigma value 1.6 (Fig.3(b)). We apply histogram equalization to the despeckled image. Then canny operator is applied to detect the edges from the histogram equalized image (Fig.3(c)). Morphological dilation is performed by using the disk shaped structuring element with radius 1 to fill the weak edges (Fig.3(d)), which yields the boundary of interested regions. In the next step, filling the region inside the object's boundary is applied (Fig.3(e)). Still there are many spurious regions present due to noise, and these are eliminated by using morphological erosion (Fig.3(f)). The Fig.3(g) depicts the recognized follicles (outlined in white) superimposed on the original image and Fig.3(h) shows the follicles annotated manually by the doctor. The Fig.4 depicts the experimental results for the proposed Method 2. In the Fig.4(a), the same original ultrasound image of the ovary as in the Fig.3(a) is considered. Initially, the image is processed with contourlet transform method yielding despeckled image (Fig.4(b)), which is then subjected to the same sequence of processing steps as in the Method 1, yielding finally the follicle detected image (Fig.4(g)). The Fig.4(h) shows the follicles annotated manually by the medical expert. There is good agreement between the segmented image and the manual segmentation done by the medical expert, which demonstrates the efficiency of the proposed algorithm.

The Fig. (5) depicts comparison of the resultant images obtained by the proposed Method 1 and Method 2 with the manual segmentation by the medical expert. We observe that the follicles, which were not segmented by Gaussian low pass filter Method 1 (Fig.5(b)), are segmented by the contourlet transform based Method 2 (Fig.5(c)). Hence, the segmentation accuracy is improved in the proposed method due to the contourlet transform based preprocessing. The Table 1 presents the comparison of experimental results of Method 1 and Method 2 for the original images in Fig.6. We observe that the Method 1 leads to more false acceptance rate (FAR) and false rejection rate (FRR).

Further, the Method 2 is found to yield more accurate results. The Figs.6 and 7 show sample results of the Method 1 and the Method 2, respectively.

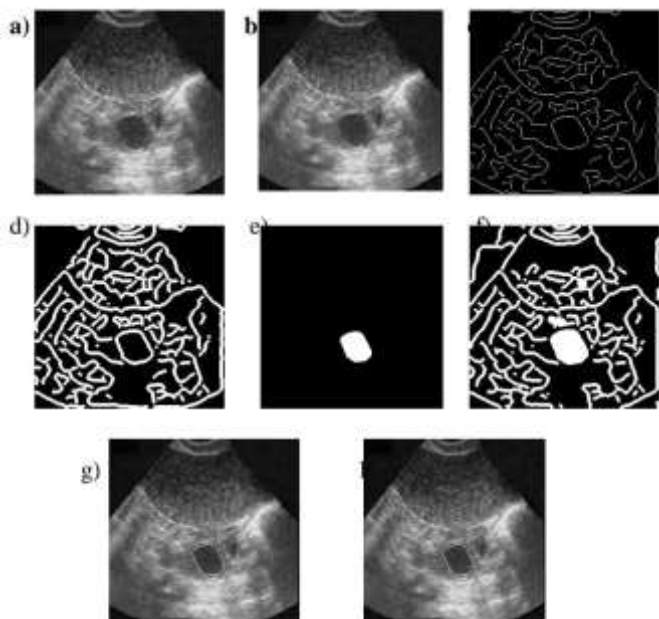


Fig.3 a) Input original ultrasound image of ovary, b) Image after applying Gaussian low pass filter (despeckling), c) Histogram equalised image after applying canny operator, d) Image after edge filling by dilation, e) Image after region filling, f) Final output image after applying erosion, g) Image showing recognized follicles (outlined in white) super imposed on the original image, h) Manual segmentation of follicles by the medical expert.

image, h) Manual segmentation of follicles by the medical expert.

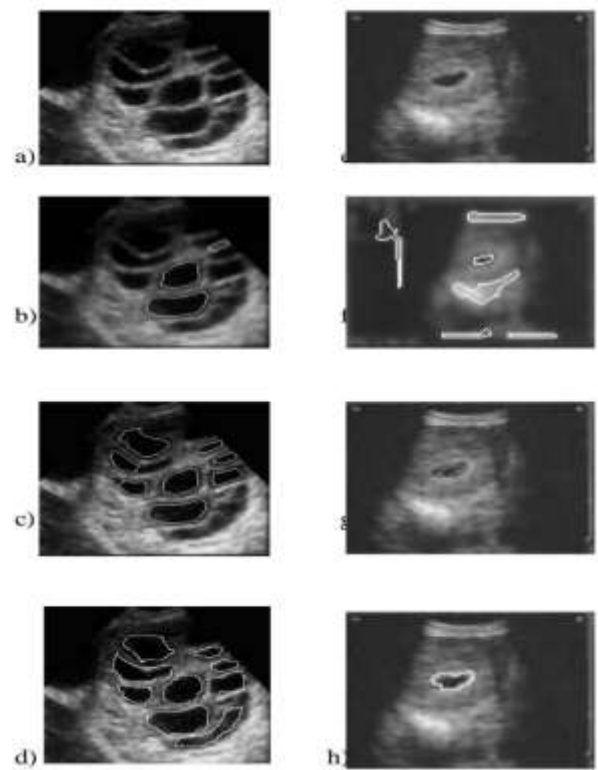


Fig.5 Comparison of resultant images of the proposed methods 1 and 2 for two different original images. (a) and (e) original image, (b)-(f) resultant images of Method 1, (c)-(g) resultant images of Method 2, (d) and (h) are manually segmented images.

Table 1. Comparison of experimental results of Method 1 and Method 2 for original images in Fig.5.

Original Image	Number of follicles detected						Manual (by expert)
	Method 1 (Gaussian low pass filter)			Method2 (Contourlet transform)			
	Total	Correct	False	Total	Correct	False	
Fig.6(a)	3	2	1	8	8	-	9
Fig.6(c)	6	1	5	1	1	-	1

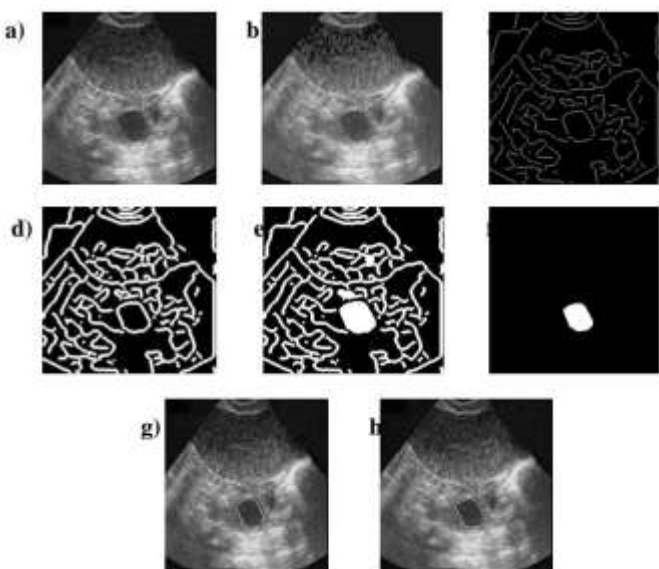


Fig.4 a) Input original ultrasound image of ovary (Fig.4(a)), b) Image after applying contourlet transform method (despeckling), c) Histogram equalized image after applying canny operator, d) Image after edge filling by dilation, e) Image after region filling, f) Final output image after applying erosion, g) Image showing recognized follicles(outlined in white) super imposed on the original

Image after applying contourlet transform method (despeckling), c) Histogram equalized image after applying canny operator, d) Image after edge filling by dilation, e) Image after region filling, f) Final output image after applying erosion, g) Image showing recognized follicles(outlined in white) super imposed on the original




Fig.6 Some typical results: a) Original images, b) Segmentation by proposed Method 1, c) Classified image, d) Manual segmentation by medical expert.

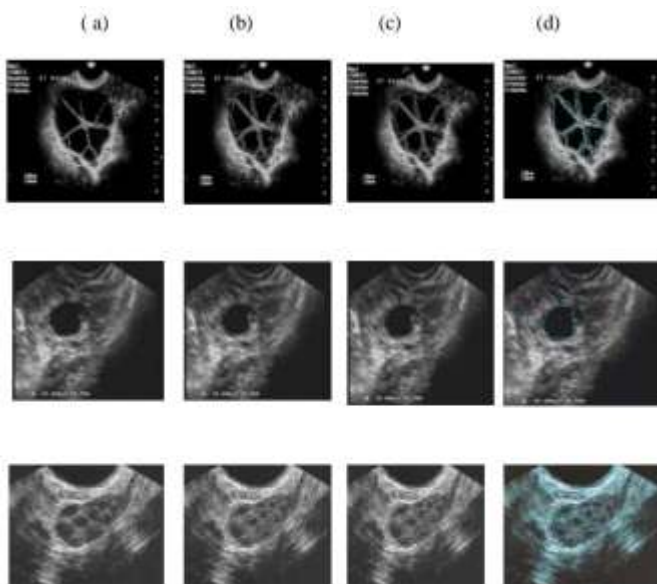


Fig.7 Some typical results: a) Original images, b) Segmentation by proposed Method 2, c) Classified image, d) Manual segmentation by medical expert.

The Table 2 shows the comparison of classification results of the proposed algorithms, namely, Method 1 and Method 2, with the manual segmentation done by the expert. The classification rate for the Method 1 is 62.3%. However, the false acceptance rate (FAR) is 22.5% and false rejection rate (FRR) is 37.6%. The classification rate for the Method 2 is 75.2% with the false acceptance rate (FAR) 22.5% and false rejection rate (FRR) 24.1%. There is good agreement between the results of the proposed method and the

manual follicle detection done by the medical expert, which demonstrates the efficacy of the proposed method.

Table 2. Comparison of segmentation results of the proposed algorithm with the manual segmentation done by the medical expert

Proposed Method	No of Input Images	No of follicles Detected (Proposed method)	No of follicles Present (medical expert)	Type I Error	Type II Error
Method 1 (Gaussian low pass filter)	25	58	93	35	23
Method2 (Contourlet transform)	25	70	93	21	23

*Type I Error: Regions are not follicles but they are recognized as follicles (FAR).

** Type II Error: Regions are follicles but they are not recognized as follicles (FRR).

4. CONCLUSION

In this paper, we have proposed a new algorithm for follicle detection in ultrasound images of ovaries. The proposed algorithm employs, Gaussian low pass filter or Contourlet transform for noise reduction, edge based segmentation and morphological operations. The classification of segmented regions for follicle detection is based on the medical knowledge about the geometric parameter, namely, the ratio R of majoraxislength to minoraxislength of follicles. The experimentation has been done on 50 sample images and the results are compared with the manual follicle detection by medical experts. The experimental results demonstrate efficacy of the method. The Contourlet transform based Method 2 yields good results due to improved segmentation as compared to the Gaussian low pass filter based Method 1.

The classification rule is based on only one geometric parameter R. Additional parametric features of follicles need to be considered for minimizing classification errors. The proposed method serves as a basis for the automatic detection of the follicles inside the ovary during entire female cycle. It will significantly reduce the burden of the experts in their everyday routines.

5. ACKNOWLEDGMENTS

The authors are indebted to the referees for their helpful comments and suggestions. Further, the authors are thankful to Malpani Infertility Clinic, Bombay and Maribor

Teaching Hospital, Maribor, Slovenia, for providing the sample images. We are grateful to Prof. Dr. Bozidar Potocnik, Faculty of Electrical Engineering and Computer Science, University of Maribor, Slovenia and Prof. Dr. Nagbhusan, Dept of Computer Science, Mysore University, Mysore, for helpful discussions. Further we are indebted to Dr. Suchitra C. Durgi, Radiologist, Dr. Chetan Durgi, Radiologist and Dr. Suvarna. M. Tegnoor, Gynecologist, Gulbarga for rendering manual segmentation of images.

REFERENCES

- [1]. Rafael C. Gonzalez, Richard E.Woods, Digital Image Processing, Second edition, Pearson Edu, (2002).
- [2]. M.Sonka, V.Halvic, R. Boyale, Image processing, analysis and machine vision. London: Chapman and hall, 1994.
- [3]. M.A.Gore, P.L.Nayudu, V.Vlaisavljevic, N.Thomus, "Prediction of ovarian cycle outcome by follicular characteristics. Stage 1", Human Reproduction, vol 10, pp 2313-2319, 1995.
- [4]. B.Potocnik, D.Zazula, The XUltra project-Automated Analysis of Ovarian ultrasound images, Proceedings of the 15th IEEE symposium on computer based medical systems (CBMS'02).
- [5]. B.Potocnik, D.Zazula, D. Korze, Automated computer assisted detection of follicles in ultrasound images of ovary, J.Med.Sys.21 (6)(1997) 445-457.
- [6]. B.Potocnik, B.Viher, D.Zazula, "Computer Assisted detection of ovarian follicles based on ultrasound images", Verzprem, Hungary, 1998, pp 24-34.
- [7]. A.Krivanek, M.Sonka, "Ovarian Ultrasound image analysis Follicle segmentation", IEEE Transactiona on medical imaging, vol 17, no 6, 1998, pp 935-944
- [8]. B.Potocnik D.Zazula, "Automated Analysis of sequence of ovarian ultrasound images Part I: segmentation of single 2d images", Image Vision and Computing, vol 20, no 3, 2002, pp 217-225.
- [9]. B.Potocnik, D.Zazula, "Automated Analysis of sequence of ovarian ultrasound images Part II prediction based object recognition from a sequence of images", Image Vision and. Computing, vol 20, no 3, 2002, pp 227-235.
- [10]. Sarty.G.E Liang.W Sonka.M and Pierson.R.A Semiautomated segmentation of ovarian follicular ultrasound images using a knowledge based algorithm, Ultrasound in medicine and biology, vol 24, no 1, 1998,pp 27-42.
- [11]. Cigale B and Zazula D, Segmentation of ovarian ultrasound images using cellular neural networks, Proc. 7th Inter .work. systems, signals and image processing (Maribor, Slovenia 2000) 33-36.
- [12]. P.S.Hiremath and Jyothi.R.Tegnoor, Automatic detection of follicles in ultrasound images of ovaries, Proc. 2nd International conference on Cognition and Recognition - ICCR08 (India, Mysore) 468-473.
- [13]. P.S.Hiremath and Jyothi R Tegnoor, Automatic detection of follicles in ultrasound images of ovaries, Proceedings of International Conference on Systemics, Cybernetics and Informatics-(ICSCI09), 7-10 Jan 2009, Hyderabad, India, pp 327-330.
- [14]. P.S.Hiremath and Prema Akkasaliger, Despeckling medical ultrasound images using the contourlet transform, 4th AMS Indian International Conference on Artificial Intelligence (IICAI-09), 16-18, Dec.2009, Tumkur, India.
- [15]. P.S.Hiremath and Jyothi. R. Tegnoor, Automatic Detection of Follicles in Ultrasound Images of Ovaries using Horizontal and Vertical Scanline Thresholding Method, Proc. 2nd International Conference on Signal and Image Processing - (ICSIP09), 12-14 Aug. 2009, Mysore, India, pp 468-473.
- [16]. P.S.Hiremath and Jyothi R Tegnoor, Follicle Detection in Ultrasound Images of Ovaries using Scanline Thresholding Method, Proc. 2nd IEEE International Conference on Advances in Computer Vision and Information Technology (ACVIT-09), 16-18 Dec. 2009, Aurangabad, India, pp 245- 251.
- [17]. P.S.Hiremath and Jyothi R Tegnoor, Recognition of Follicles in Ultrasound Images of Ovaries using Geometric Features, Proc. 2nd IEEE International Conference on Biomedical and Pharmaceutical Engineering (ICBPE-09), 2-4 Dec. 2009, Singapore, ISBN 978-1-4244-4764-0/09.
- [18]. P.S.Hiremath and Jyothi R Tegnoor, Proc. National Seminar on Recent Trends in Image Processing and Pattern Recognition (RTIPPR-2010), 15-16 Feb. 2010, Bidar, India, pp 114-120.
- [19]. P.S.Hiremath and Jyothi R Tegnoor, Automatic Detection of Follicles in Ultrasound Images of Ovaries using HRGMF Based Segmentation, International Journal of Multimedia, Computer Vision and Machine Learning. Vol 1 No1 June 2010 pp 83-87