

## Diabetic Retinopathy

Vaishnavi Kukutkar<sup>1</sup>, Rehan Pathan<sup>2</sup>, Shubham Mansute<sup>3</sup>, Madan Bhendare<sup>4</sup>, Jyoti Kubade<sup>5</sup>

<sup>1,2,3,4,5</sup>Student, Dept. of Computer Science & Engineering, Datta Meghe Institute of Engineering, Technology & Research, Wardha, Maharashtra, India

\*\*\*

**Abstract** - Here we address the detection of Hemorrhages and microaneurysms in color fundus images. In pre-Processing we separate red, green, blue color channel from the retinal images. The green channel will pass to the further process. The green color plane was utilized in the analysis since it shows the simplest contrast between the vessels and therefore the background retina. Then we extract the GLCM (Gray Level Co-Occurrence Matrix) feature. Within the GLCMs, several statistics information are derived using the various formulas. These statistics provide information about the feel of a picture, like Energy, Entropy, Dissimilarity, Contrast, Inverse difference, correlation Homogeneity, Auto correlation, Cluster Shade Cluster Prominence, Maximum probability, Sum of Squares are going to be calculated for texture image. After feature Extraction, we offer this feature to classifier. Finally it'll predict about the retinal whether it's hemorrhages or microaneurysms. After predicting problems in the retinal image we'll localize the affected place. For segmenting the localized place we'll use adaptive thresholding segmentation.

diagnosis of diabetes, 80% of type 2 diabetics and nearly all type 1 diabetics show some signs of retinopathy. While these numbers are eye-opening, diabetics can decrease their risk of retinopathy and slow the progression of the disease after it has begun with tight glucose control.

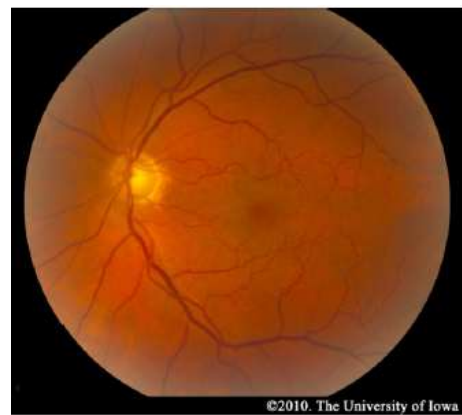

Figure 1.1: Normal Fundus

**Key Words:** Image representation, dissimilarity space, class learning.

### 1. INTRODUCTION

#### 1.1 Overview

Diabetic retinopathy (DR) is a vascular disease of the retina which affects patients with diabetes mellitus. It is the number one cause of blindness in people between the ages of 20-64 in the United States. It is, therefore, a worthwhile topic for all medical students to review. Diabetes mellitus is extremely common, so it is not surprising that DR affects 3.4 percent of the population (4.1 million individuals). Of the millions of people with DR, nearly one-fourth have vision-threatening disease. The likelihood of developing diabetic retinopathy is related to the duration of the disease. Type 2 diabetes has an insidious onset and can go unnoticed for years. As a result, patients may already have DR at the time of diagnosis. Type 1 diabetics, on the other hand, are diagnosed early in the course of their disease, and they typically do not develop retinopathy until years after the diagnosis is made. The risk of developing retinopathy increases after puberty. Twenty years after the

### Classification

Diabetic retinopathy falls into two main classes: nonproliferative and proliferative. The word "proliferative" refers to whether or not there is neovascularization (abnormal blood vessel growth) in the retina. Early disease without neovascularization is called nonproliferative diabetic retinopathy (NPDR). As the disease progresses, it's going to evolve into proliferative diabetic retinopathy (PDR), which is defined by the presence of neovascularization and features a greater potential for serious visual consequences.

#### NPDR

Hyperglycemia results in damage to retinal capillaries. This weakens the capillary walls and results in small out pouching of the vessel lumens, known as microaneurysms. Microaneurysms eventually rupture to make hemorrhages deep within the retina, confined by the interior limiting membrane (ILM). Because of their dot-like appearance, they're called "dot-and-blot" hemorrhages. The weakened vessels also become leaky, causing fluid to seep into the retina. Fluid deposition under the macula, or macular edema, interferes with the macula's normal function and may be a common explanation for vision loss in those with DR. Resolution of fluid lakes can leave behind sediment, almost like a receding river after a flood. This sediment consists of

lipid byproducts and appears as waxy, yellow deposits called hard exudates. As NPDR progresses, the affected vessels eventually become obstructed. This obstruction may cause infarction of the nerve fiber layer, leading to fluffy, white patches called cotton spots (CWS).

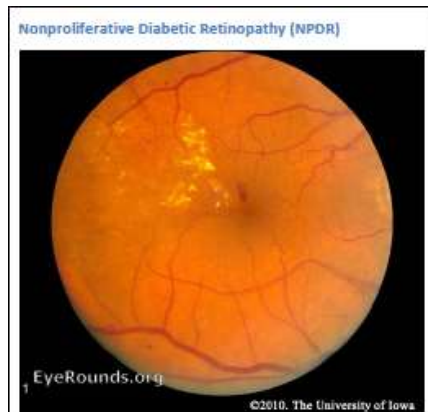

Figure 1.2: NPDR

### Morphological Processing

Morphological processing is the most common method used for detection of microaneurysm. Morphological processing is a collection of techniques that can be used for image component extraction. In 1996, Spencer et al. [11] used morphological processing which detects microaneurysms present in fluorescein angiograms. After preprocessing stage, a bilinear top-hat transformation and matched filtering are used to provide an initial segmentation of the images. Then Thresholding is used to produce a binary image that contains candidate microaneurysms. Then a novel region-growing algorithm results in the final segmentation of microaneurysms.

Then Frame et al. [12] produced a list of features like shape features and pixel-intensity features on each candidate. After that the classifier is used to classify each candidate as microaneurysm and non-microaneurysm by using these features.

Niemeijer et al. [6] used a hybrid approach to detect the red lesions by combining the prior works by Spencer et al. [11] and Frame et al. [12] with two important new contributions. Their first contribution is the use of new red lesion candidate detection system which is based on pixel classification. Blood vessels and red lesions are separated from the background by using this technique. Remaining objects are considered as possible red lesions after removal of vasculature. Their second contribution is the addition of a large number of new features to those proposed by Spencer Frame. Then k-nearest neighbor classifier is used to classify the detected candidate objects. The images for the dataset are taken from the hospital. This method has achieved 100% sensitivity and 87% specificity but the time required is more for initial detection of red lesions.

Then Zhang and Fan [13] proposed a spot lesion detection algorithm that uses multiscale morphological processing. Using scale-based lesion validation, blood vessels are removed. This algorithm was tested on 30 retinal images and it has achieved the sensitivity of 84.10% and predictive value of 89.20%.

Karnowski et al. [14] proposed a morphological reconstruction method for the segmentation of retinal lesions. In this method, the segmentation is performed by using ground-truth data at a variety of scales determined, to separate nuisance blobs from true lesions. The ground truth data is used to design post-processing classifiers to separate the machine segmented results into nuisance and actual lesion classes. This segmentation result is used to classify the images as "normal" or "abnormal". This method was tested on 86 retinal images and these images are taken from the hospital. This method has achieved a sensitivity of 90% and specificity of 90%. The weakness of this method is that classification features for the post-processing steps is inaccurate so this method can be improved on more realistic dataset.

Kande et al. [15] proposed an approach that takes into account the advantages of pixel-based classification and morphological based detection. Local entropy thresholding algorithm is used to distinguish between enhanced red lesion segments and the background. Then morphological top-hat transformation is used to suppress the blood vessels and then SVM (Support Vector Machine) is used to classify the red lesions from other dark regions. This approach takes the same time as proposed in [11] and [12] and performs better. The author has selected 80 retinal images randomly from the Clemson, DIARETDB0 and DIARETDB1 databases. The sensitivity was 96.22% and specificity was 99.53% of this approach.

### 1.2 Motivation

The prolonged diabetes leads to the formation of microaneurysms and subsequently it leads to exudates as well as hemorrhages. These are the features of DR and that they may cause severe vision loss or maybe blindness. In order to avoid these complications, it is very important to detect DR early. This can be done by an accurate detection of microaneurysms. It is very difficult to detect the exudates clearly, because they are tiny spots on the retina. Also, the detection of hemorrhages is very challenging. The texture of hemorrhages and macula is almost the same. So, we'd like to possess robust algorithms which detect these features.

### 1.3 Objectives

The primary objective of evaluating and managing diabetic retinopathy is to prevent, retard, or reverse visual loss, thereby maintaining or improving vision-related quality of life. In computer based retinal image analysis system, image processing techniques are used in order to facilitate and

improve diagnosis. Manual analysis of the images can be improved and problem of detection of diabetic retinopathy in the late stage for optimal treatment may be resolved.

Based on these the main objectives of the project are as follows:-

- i. Detection of macular region.
- ii. Detection of retinal blood vessels.
- iii. Early detection of diabetic retinopathy.
- iv. To predict intensity of infection in eye using feature extraction.
- v. Detection of Hemorrhages and Microaneurysms in color fundus image.

## 2. METHODOLOGY

### 2.1 Problem Definition

- Diabetic Retinopathy (DR) is one of the leading causes of blindness in the industrialized world.
- Early detection is the key in providing effective treatment.
- However, the current number of trained eye care specialists is inadequate to screen the increasing number of diabetic patients.
- In recent years, automated and semi-automated systems to detect DR with color fundus images have been developed with encouraging, but not fully satisfactory results.

### 2.2 Proposed Approach

#### Microaneurysm Detection

Automated microaneurysm detection is very useful in diagnosing the diabetic retinopathy for the prevention of blindness. With the help of automated system, the work of ophthalmologists can be reduced and the cost of detection of diabetic retinopathy can also be reduced. Most of the existing methods of microaneurysms detection work in two stages: microaneurysm candidate extraction and classification. First stage requires image preprocessing for the reduction of noise and contrast enhancement. Image preprocessing is performed on the green color plane of RGB image because in green color plane microaneurysms have the higher contrast with the background. After that candidate regions for microaneurysms are detected. Then blood vessel segmentation algorithms are applied to extract blood vessel from the candidates for the reduction in false positives because many of the blood vessels may appear as false positives in the preprocessed image. Then feature analysis is used in which feature extraction and feature selection is performed to detect the microaneurysms. In second stage, the classification algorithm is applied to categorize these features into microaneurysm candidate (abnormal) and non-microaneurysm candidate (normal). The probability is

estimated for each candidate using a classifier and a large set of specifically designed features to represent a microaneurysm. In general the process for the detection of microaneurysms is concluded in Figure given below.

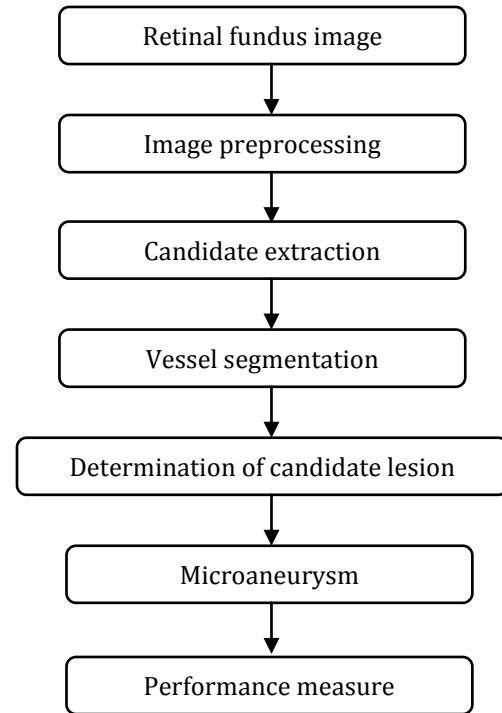


Figure 2.2.1: Microaneurysm Detection

#### Algorithm Description

##### Phase 1

##### Image Pre-processing

Images are enhanced by sharpening and removing unwanted outliers.

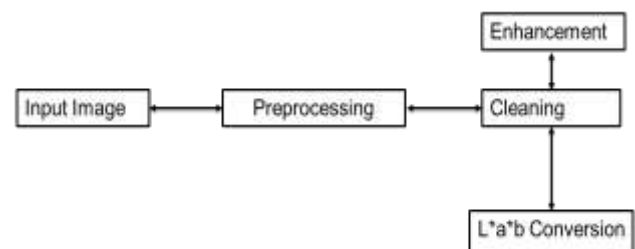


Figure 2.2.2: Image Pre-processing

##### Phase 2

##### Segmentation

Image will be segmented to fetch out the image edges and then detected all required parameters.

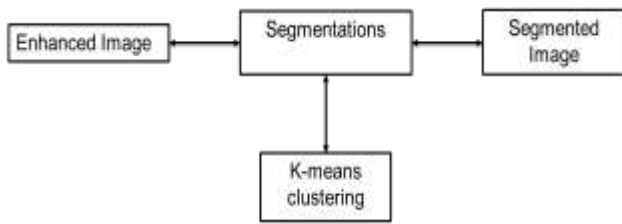


Figure 2.2.3: Segmentation

**Phase 3**

**Recognition and Classification**

Once the image is segmented it can be tested to recognize it first and then classify it using SVM algorithm.

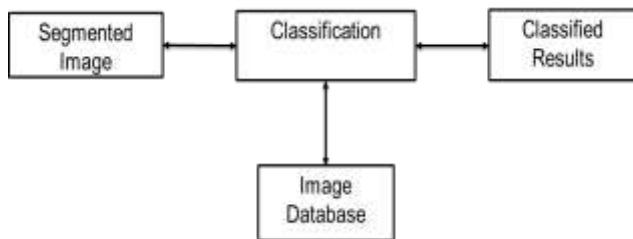


Figure 2.2.4: Recognition and Classification

**3. IMPLEMENTATION DETAILS**

**3.1 Test Environment**

Processor	Intel® Core™ i3 Processor 2.40 GHz
RAM	4 GB
Operating System	64 bit
Programming Tool	MATLAB R 2015 a

**3.2 MATLAB**

Millions of engineers and scientists worldwide use MATLAB® to analyze and design the systems and products. MATLAB is in automobile active safety systems, interplanetary spacecraft, health monitoring devices, smart power grids. It is used for machine learning, signal processing, image processing, computer vision, computational finance, control design, robotics, and much more. MATLAB is stands for Matrix Laboratory. Clave Molar is a mathematician and a computer programmer has invented MATLAB in mid 1970s. MATLAB is a high performance language for technical computing. It takes part in computation, visualization, and programming in an easy-to-use environment where problems and solutions are expressed in familiar mathematical code. Typical uses include: Math and computation. MATLAB is programmable

software for multi-paradigm numerical environment. This software is developed by the Math Works.

**4. RESULT AND DISCUSSION**

In figure 4.1, the main GUI is shown which has seven buttons to perform different operations on the fundus image.




Figure 4.1: Main GUI Window

Figure 4.2 shows the window after clicking the “Input Image” button to fetch dataset.

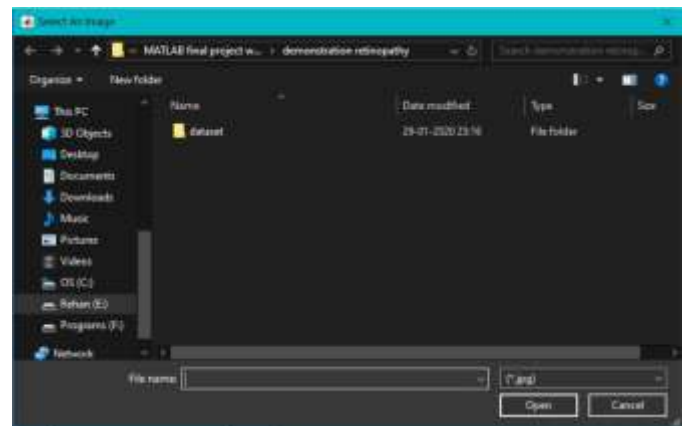


Figure 4.2: Fetching Dataset

Figure 4.3 shows the working of Neural Network algorithm on a fundus image to train the dataset for further processing.

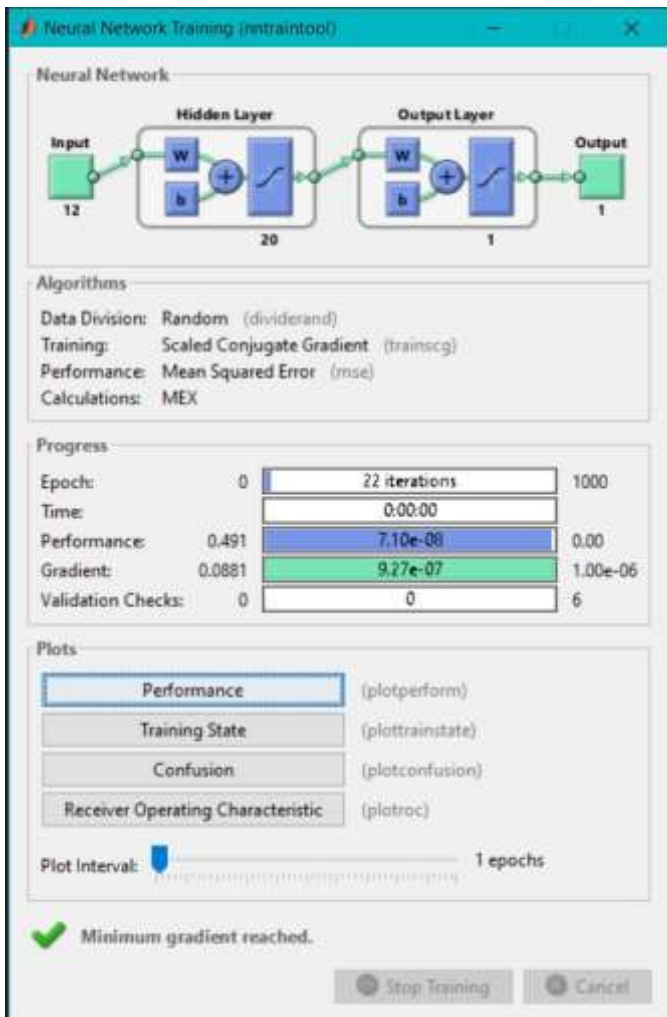

Figure 4.3: Working of Neural Network on a Fundus Image

In Figure 4.4, RGB channels are extracted and stored by clicking on the "Preprocessing" tab.

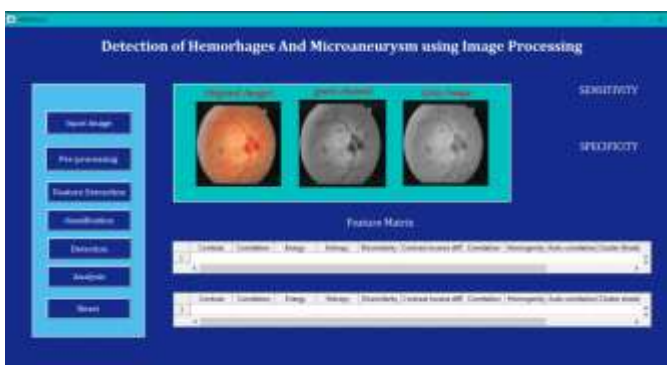

Figure 4.4: RGB Channel Extraction of an Input Image

By clicking on "Feature Extraction" button, different features such as contrast, energy, etc. are extracted and displayed in a table as shown in figure 4.5.

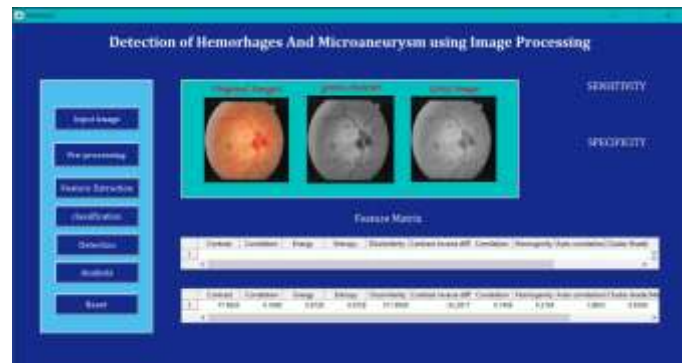

Figure 4.5: Feature Extraction of Fundus Image

The "Classification" tab will navigate the user to actual disease, for example, Hemorrhages, in the fundus image which is shown in figure 4.6.

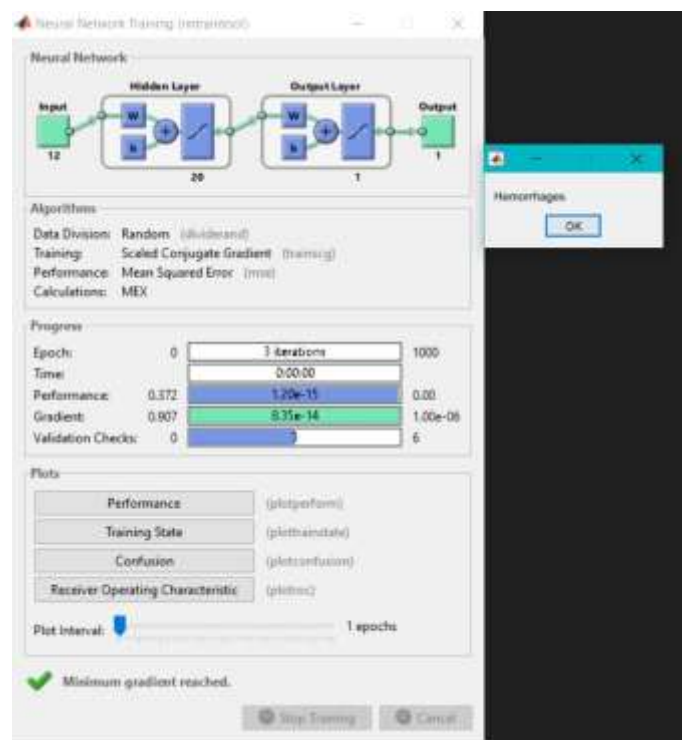

Figure 4.6: Detection of Actual Disease

Which site or vessel of fundus image contains the problem is detected and it is shown by separating the background and foreground, as shown in figure 4.7.

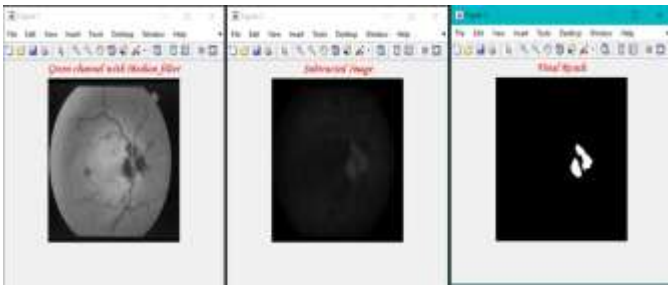


Figure 4.7: Detecting actual sites of problem

## 5. CONCLUSIONS

Prolonged diabetes leads to DR, where the retina is damaged due to fluid leaking from the blood vessels. Usually, the stage of DR is judged based on blood vessels, exudes, hemorrhages, microaneurysms and texture. In this paper, we have discussed different methods for features extraction and automatic DR stage detection. An ophthalmologist uses an ophthalmoscope to visualize the blood vessels and his or her brain to detect the DR stages. Recently digital imaging became available as a tool for DR screening. It provides high quality permanent records of the retinal appearance, which can be used for monitoring of progression or response to treatment, and which can be reviewed by an ophthalmologist, digital images have the potential to be processed by automatic analysis systems. A combination of both accurate and early diagnosis as well as correct application of treatment can prevent blindness caused by DR in more than 50% of all cases. Automatic detection of microaneurysm presents many of the challenges. The size and color of microaneurysm is very similar to the blood vessels. Its size is variable and often very small so it can be easily confused with noise present in the image. In human retina, there is a pigmentation variation, texture, size and location of human features from person to person. The more false positives occur when the blood vessels are overlapping or adjacent with microaneurysms. So there is a need of an effective automated microaneurysm detection method so that diabetic retinopathy can be treated at an early stage and the blindness due to diabetic retinopathy can be prevented.

## REFERENCES

- [1] S. Wild, G. Roglic, A Green, "Global prevalence of diabetes: estimates for the year 2000 and projections for 2030," *Diabetes Care*, 27, pp.1047- 1053, 2004.
- [2] S. R. Nirmala, M. K. Nath, and S. Dandapat, "Retinal Image Analysis: A Review," *International Journal of Computer & Communication Technology (IJ CCT)*, vol-2, pp. 11-15, 2011.
- [3] National Eye Institute, National Institutes of Health, "Diabetic Retinopathy: What you should know," Booklet, NIH Publication, no: 06-2171, 2003.
- [4] A. D. Fleming, K. A. Goatman, and J. A. Olson, "The role of haemorrhage and exudate detection in automated grading of diabetic retinopathy," *British Journal of Ophthalmology*, vol 94, no. 6, pp. 706- 711, 2010.
- [5] A. D. Fleming, S. Philip, K. A. Goatman, J. A. Olson, and P. F. Sharp, "Automated microaneurysm detection using local contrast normalization and local vessel detection," *IEEE Trans. Med. Imag.*, vol. 25, no. 9, pp. 1223–1232, Sep. 2006.
- [6] M.Niemeijer, B. V. Ginneken, J. Staal, M. S. A. Suttorp-Schulten, and M. D. Abramoff, "Automatic detection of red lesions in digital color fundus photographs," *IEEE Trans. Med. Imag.*, vol. 24, no. 5, pp. 584– 592, May 2005.
- [7] M. J. Cree, J. A. Olson, K. C. McHardy, J. V. Forrester and P. F. Sharp, "Automated microaneurysms detection," *IEEE conference*, pp. 699-702, 1996
- [8] A. Mizutani, C. Muramatsu, Y. Hatanaka, S. Suemori, T. Hara, and H. Fujita, "Automated microaneurysm detection method based on double ring filter in retinal fundus images," in *Proc. SPIE, Med. Imag, Imag, Computer-Aided Diagnosis*, vol. 7260, 2009.
- [9] K. Ram, G. D. Joshi and J. Sivaswamy, "A successive clutter rejection based approach for early detection of diabetic retinopathy," *IEEE Transaction on Biomedical Engineering*, vol. 58, no. 3, pp. 664-673, Mar. 2011
- [10] M. Esmaeili, H. Rabbani, A. M. Dehnavi, and A. Dehghani, "A new curvlet transform based method for extraction of red lesions in digital color retinal images," in *Proc. ICIP*, pp.4093-4096, 2010.
- [11] T. Spencer, J. Olson, K. McHardy, P. Sharp, and J. Forrester, "An image processing strategy for the segmentation and quantification in fluorescein angiograms of the ocular fundus," *Comput. Biomed. Res.*, vol. 29, pp. 284–302, 1996.
- [12] A. Frame, P. Undrill, M. Cree, J. Olson and K. McHardy, P. Sharp, and J. Forrester, "A comparison of computer based classification methods applied to the detection of microaneurysms in ophthalmic fluorescein angiograms," *Comput. Biol. Med.*, vol. 28, pp. 225–238, 1998.
- [13] X. Zhang and G. Fan, "Retinal Spot Lesion Detection Using Adaptive Multiscale Morphological Processing," in *Proc. ISVC (2)*, pp.490-501, 2006.
- [14] T. P. Karnowski, V. P. Govindasamy, K. W. Tobin, E. Chaum, M. D. Abramoff, "Retina Lesion and Microaneurysm Segmentation using Morphological Reconstruction Methods with Ground-Truth Data," *Conf Proc IEEE Eng Med Biol Soc* 1, pp. 5433-5436, 2008.
- [15] G.B. Kande, S.S. Tirumala, P.V. Subbaiah, and M.R. Tagore, "Detection of Red Lesions in Digital Fundus Images," in *Proc. ISBI*, pp.558-561, 2009.