

EARLY DETECTION OF GLAUCOMA USING IMAGE PROCESSING

Dr. D. Deepa¹, S. Swetha²

Department of Electronics and Communication Engineering, Bannari Amman Institute of Technology, Sathyamangalam

Abstract - Glaucoma, an eye illness is caused as a result of neuro degeneration of eye's optic nerve. Optic nerve transmits images to the brain. If the damage continues it may cause complete blindness. Parameters involved in assessing glaucoma are intra ocular pressure (IOP), visual field and cup-to-disc ratio (CDR). Glaucoma causes an increase in CDR value, thus affecting the peripheral vision loss. With the help of Image Processing techniques, CDR values can be estimated. These CDR values can be used to detect the presence of Glaucoma. There are a number of common image processing techniques involved such as pre-processing, feature extraction and classification. The classifier used is k-nearest neighbour because the process is simple. The requirement of k-nearest neighbour algorithm is several types of input data namely number of neighbour (k), distance matrix and a dataset. Euclidean distance is used to calculate the distance matrix.

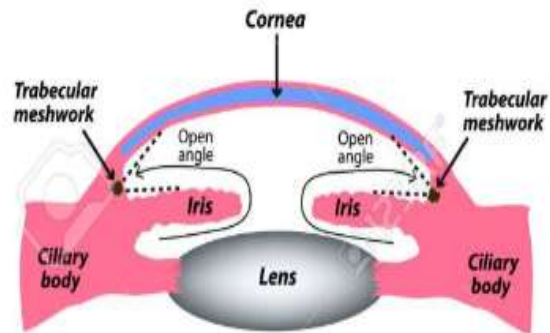


FIG 1.1: OPEN-ANGLE GLAUCOMA

Key Words: Glaucoma, CDR, Features, KNN, Classification

1.2.2 Angle Closure Glaucoma:

It may be called as intense or interminable edge conclusion or tight point Glaucoma. The channel space between iris and cornea becomes excessively thin and this leads to abrupt development of weight in eye.

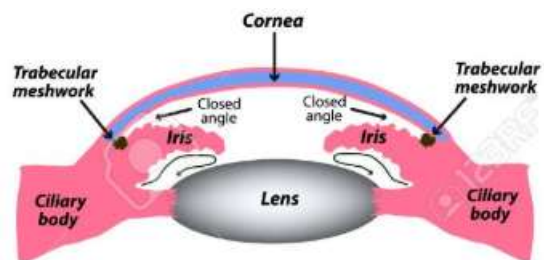


FIG 1.2: ANGLE CLOSURE GLAUCOMA

1.INTRODUCTION

1.1 GLAUCOMA

Glaucoma is an eye illness. It affects eye's optic nerve after which it deteriorates. Due to this, there is a development of weight at the interior of eye. The weight at the interior of eye is called intra ocular pressure. This causes harm to the optic nerve. If this is not cured at the early stage, glaucoma can cause complete blindness.

1.2 TYPES OF GLAUCOMA

Glaucoma is of two main types:

1. Open-angle Glaucoma
2. Angle Closure Glaucoma

1.2.1 Open-angle Glaucoma:

It is the most common type and is also called as wide-edge glaucoma. The trabecular meshwork(channel structure in eye) looks normal, but liquid doesn't stream out like it should.

1.3 PROPOSED GLAUCOMA DETECTION SYSTEM

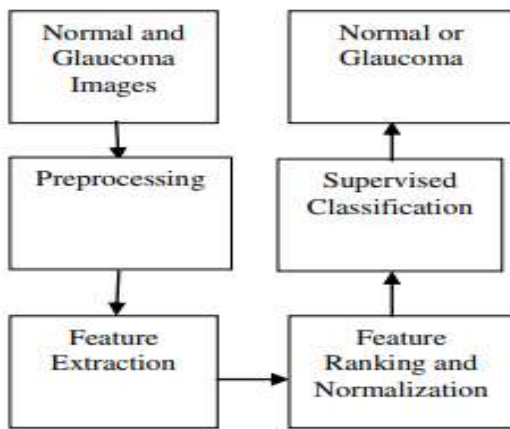


FIG 1.3: PROPOSED SYSTEM

Preprocessing: Preprocessing is usually done before the main processing of the image. It is normally done to remove unwanted portions of the image to be processed. This helps in improvement of the image.

Feature Extraction: Feature extraction helps in extraction of the region of interest which is represented for further processing.

Optic Cup Segmentation: The segmentation of Optic Cup is quite challenging because of density of blood vessels covering parts of cup and gradual change in colour intensity between rim and the cup. Sometimes the kinks present in the blood vessels help in detection of cup boundaries.

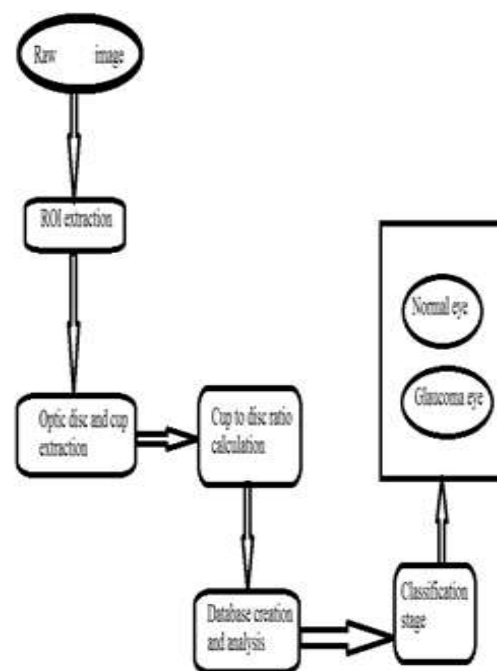
Optic Disc Segmentation : Optic Disc is considered as one of the most fundamental part of retinal image. The detection of Optic Disc is considered as a pre-processing component in various methods of image segmentation of retinal images. It is a most common step in retinal image screening procedures. The Optic Disc is of vertical oval(elliptical) shape. It is divided into two separate zones: central zone (cup) and peripheral zone (neuroretinal rim). Presence of Glaucoma is indicated by the variations in colour, shape or depth of Optic Disc.

Cup to Disc Ratio: The CDR calculation is used in optometry and ophthalmology to detect the glaucoma movement. There is a region called optic circle which belongs to anatomical area of eye's "vulnerable side". The "vulnerable side" is the region where the optic vein and nerve enters the retina. The CDR ratio deals with the distance between the cup part of the

optic circle and the width of optic plate. The high value of CDR infers the risk of Glaucoma.

Classification: This is an important step in which the decision is made. The classifier used here is k-nearest neighbour which is a simple classifier. The requirement of k-nearest neighbour algorithm is several types of input data namely number of neighbour (k), distance matrix and a dataset. Euclidean distance is used to calculate the distance matrix.

2.1 FLOW DIAGRAM



The image to be processed is obtained as a raw image. The region of interest is extracted from the input image. The region of interest in glaucoma detection is Optic disc and cup. These are used in the estimation of CDR values. Based on the CDR values, the input image is classified as Normal eye or Glaucoma affected eye.

There are a number of methods available in image processing. The techniques used in detection of glaucoma are Image Enhancement, Image Segmentation, Feature extraction, Morphology, etc.

Degeneration of optic nerves causes Glaucoma. So the fall in circulatory system to the optic nerve accommodate the visual field surrenders related with glaucoma. Morphological features of fundus images can be used to detect the damage

caused to optic nerve fibre. Glaucoma can be detected using the following features,

1. Cup-to-disc ratio (CDR)
2. Ratio between area of blood vessels in inferior-superior side and the nasal-temporal side
3. Ratio of distance between the optic disc center and optic nerve head to diameter of the optic disc

The main parts involved in detection of glaucoma are Optic Cup and Optic Disc. Image Segmentation process is carried out for Optic Cup and Optic Disc. This helps in calculation of CDR (cup-to-disc) value. Changes in CDR value are viewed as the significant sign of glaucoma.

3. OUTPUT DESCRIPTION

3.1 INPUT IMAGE ACQUISITION

FIG 3.1 shows the images given as input to detect the presence of Glaucoma.

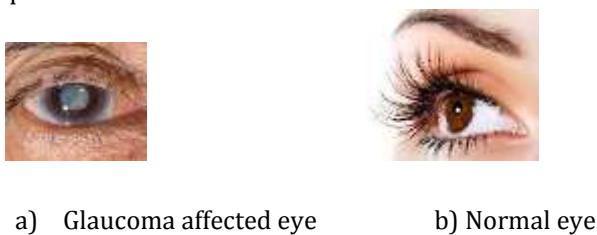

FIG 3.1: INPUT IMAGES

From the above image, the glaucoma is detected and the corresponding disk segment image, disc boundary, cup image and the cup boundary is identified.

3.2 IMAGE WITH GLAUCOMA

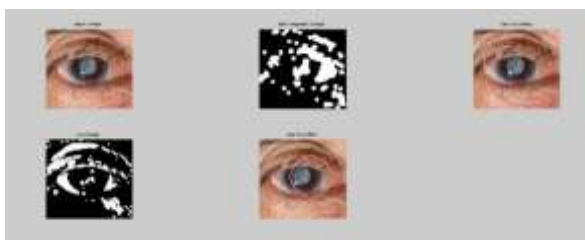

FIG 3.2: OUTPUT IMAGE OF A GLAUCOMA DETECTED EYE

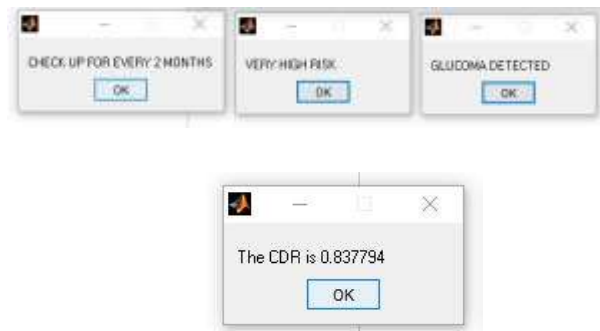


FIG 3.3: DETECTION OF GLAUCOMA

The output image acquired for Glaucoma affected eye is given in FIG 3.3. As per the details given in FIG 3.3, the presence of Glaucoma is detected. The key factor for glaucoma detection is the CDR value. CDR value greater than 0.4 indicates the presence of Glaucoma. Since the value here is 0.837794 which is greater than 0.4, there is a risk of Glaucoma.

3.3 IMAGE WITHOUT GLAUCOMA



FIG 3.5: OUTPUT IMAGE OF A NORMAL EYE

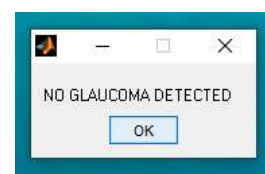
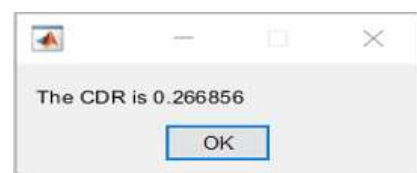

FIG 3.6: ABSENCE OF GLAUCOMA

The output image for a normal eye is represented in FIG 3.5. The CDR value here is 0.266856. The CDR value being less than 0.4, there is no risk of Glaucoma. These details are depicted in FIG 3.6

Table 3.1: CDR Values

CDR	RESULT
0.762696	Glaucoma
0.266856	Normal
0.821629	Glaucoma
0.588591	Glaucoma
0.138271	Normal
0.362347	Normal
0.593860	Glaucoma
0.260040	Normal
0.379974	Normal
0.837794	Glaucoma

About 10 images were taken as input. And as per the CDR values the presence of Glaucoma is detected. When the CDR value falls in the range of 0.1 to 0.4, then there is no risk of Glaucoma. The eye is Normal. Whereas when the CDR value is above 0.4, then there is a risk of Glaucoma.

4. CONCLUSION

Glaucoma occurs as a result of neuro degeneration of eye's optic nerve. This may cause permanent vision loss. Hence, detection of this disease at the early stage helps in prevention of vision loss. In this paper, CDR is considered as the main parameter to detect the presence of Glaucoma. There are many features which contribute to the detection of Glaucoma.

REFERENCES

- [1] Kevin Noronha, Jagadish Nayak, S.N. Bhat, "Enhancement of retinal fundus Image to highlight the features for detection of abnormal eyes"
- [2] Sangyeol Lee, Michael D. Abr'amoff, and Joseph M. Reinhardt. "Validation of Retinal Image Registration Algorithms by a Projective Imaging Distortion Model" 29th Annual International Conference of the IEEE EMBS Cit² Internationale, Lyon, France August 23-26, 2007
- [3] S. Sekhar, "Automated localisation of retinal optic disk using hough transform", Department

of Electrical Engineering and Electronics, University of Liverpool, UK.

[4] Zhuo Zhang, "ORIGA-light : An Online Retinal Fundus Image Database for Glaucoma Analysis and Research", 32nd Annual International Conference of the IEEE EMBS Buenos Aires, Argentina, August 31 - September 4, 2010

[5] VahabiZ, "The new approach to Automatic detection of Optic Disc from non-dilated retinal images" Proceedings of the 17th Iranian Conference of Biomedical Engineering (ICBME2010), 3-4 November 2010

[6] Zafer Yavuz, "RETINAL BLOOD VESSEL SEGMENTATION USING GABOR FILTER AND TOPHAT TRANSFORM", 2011 IEEE 19th Signal Processing and Communications Applications Conference (SIU 2011) 978-1-4577-0463-5/11 ©2011 IEEE

[7] Nilanjan Dey, "Optical Cup to Disc Ratio Measurement for Glaucoma Diagnosis Using Harris Corner", ICCNT12

[8] Harris C, Stephens, M., 1988, A Combined Corner and Edge Detector, Proceedings of 4th Alvey Vision Conference

[9] Konstantinos G Derpanis, 2004, The Harris Corner Detector

[10] R. Geetha Ramani, "Automatic Prediction of Diabetic Retinopathy and Glaucoma through Retinal Image Analysis and Data Mining Techniques"