

Retinal Blood Vessel Extraction and Radius measurement

Varsharani Gore¹

¹MTech (EC), SGGSI&T, Nanded

Abstract – The most common health issue among the people nowadays is diabetes. The diabetic retinopathy is among one of the disease lead to sight loss. The blood vessels are representation of retina pathology. Accurate measurement of vessels diameters on retinal images plays an important part in diagnosing cardiovascular disease as well as it shows early signs of certain systemic disease, such as diabetics and hypertension. This paper represents the algorithm for the detection and radius measurement of retinal blood vessels, which is general enough that it can be applied to high resolution fundus photographs. Firstly, preprocessing operations are performed on fundus images, then simple vessels segmentation technique, formulated in language of 2D Median Filter. Then after by using morphological operations and calculated mean values, radius is measured.

Key Words: Blood vessels, 2D Median Filter, Radius.

1. INTRODUCTION

Variations in blood vessel diameters occur as part of the autonomous control of blood flow in healthy subjects and at different stages. The diabetic retinopathy can be indicated by changing the diameter of retinal blood vessels within fundus image. One of the most powerful sign of diabetic retinopathy is the unusual changing in the width along a vein. In this paper, pre-processing operation is performed on high resolution fundus image, then 2D median filter for blood vessel extraction, for classification of blood vessel the diameter of blood vessel is calculated. For observing the result, the database is taken from IDRID, it consists 81 colour fundus image with signs of DR and 164 without sign of DR. This dataset provides information on the disease severity of diabetic retinopathy, and diabetic macular edema. This makes it perfect for development and evaluation of image analysis algorithm for early detection of diabetic retinopathy.

2. METHODOLOGY

The retinal vasculature is composed of the arteries and veins with their tributaries which are visible within the retinal image. The segmentation and measurement of the retinal vasculatures of primary interest in the diagnosis and treatment of a number of systemic and ophthalmologic conditions. The accurate segmentation of the retinal blood vessels is often an essential prerequisite step in the identification of retinal anatomy and pathology. In this algorithm, the Green channel is extracted from RGB image

because green channel has high intensity as compared to Red and Blue.

$$g = \frac{G}{R + G + B} \quad (1)$$

Here g is Green channel and R, G and B are Red, Green and Blue respectively. Then the complement function is used for enhancing the blood vessels of the retina.

$$A^c = \{w | w \notin A\} \quad (2)$$

Here A^c is a complement, w is the element of A, \notin stands for not an element of A.

A contrast-limited adaptive histogram equalization “CLAHE” is applied for contrast enhancement. It operates on small regions in the image.

$$h(v) = \text{round} \left(\frac{cdf(v) - cdf_{min}}{(M * N) - cdf_{min}} \times (L - 1) \right) \quad (3)$$

Here cdf_{min} is the minimum value of the cumulative distribution function, M*N gives the image’s number of pixels and L is the number of gray levels.

As binary images may contain numerous imperfections, Morphological image processing is used to pursue the goals of removing these imperfections by accounting for the form and structure of the image. Structuring element is used for highlighting the blood vessels from fundus image.

$$I_{dilated}(i, j) = \max_{f(n, m)} = I(i + n, j + m) \quad (4)$$

$$I_{eroded}(i, j) = \min_{f(n, m)} = I(i + n, j + m) \quad (5)$$

To extract the vessels which lie in the optic disk region, optic disk is removed. After performing the optic disk removal operation, a 2D Median filtering operation is applied to reduce the noise.

$$y[m, n] = \text{median}\{x[i, j], (i, j) \in \omega\} \quad (6)$$

Here w represents a neighborhood centered around location (m,n) in the image.

Then for image segmentation thresholding method is used. Global thresholding can be applied to those retinal images where there is uniform contrast distribution of background and foreground pixels.

$$T = 0.5(m1 + m2) \quad (7)$$

At the end for calculating the diameter of retinal blood vessels Euclidean Distance Transform is used.

3. RESULTS

The performance of the whole procedure is tested. These methodologies were evaluated using publically available dataset IDRID. This algorithm achieves a True positive rate of 100%, False positive rate of 0%. In this test the accuracy is determined by convolution neural network is 98%.

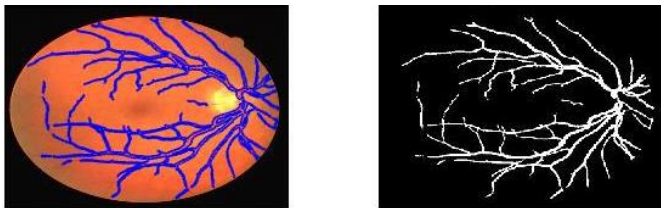


Fig -1: Segmented blood vessels

Mean Radius = 3.8 pixels.
Mean Diameter = 7.6 pixels.

3. CONCLUSIONS

In this paper, a new way is determine for blood vessels segmentation and diameter calculation. The use of enhancement technique CLAHE, gives a better enhanced image which is required before the segmentation process. Global thresholding is used to get well segmented image. The morphological tactics is used to remove uneven illumination, then use 2D Median filtering to remove noise in image. The width of each vessel segment is estimated using Euclidean Distance Transform. The suggested algorithm simple, fast and easy to applied. In this paper, the given algorithm is performed only the overall area of the retinal blood vessels our future scope is to convert this algorithm for infected area of the retinal blood vessels.

REFERENCES

- [1] Kundtson MD, Klein R, Wong TY et al. "Variation associated with measurement of retinal vessel diameters at different points in the pulse cycle" Br J Ophthalmol.2004;88:57-61.
- [2] J. Sivakumar and J. Jenov "Automated Extraction of Blood Vessels In retinal image" Internal Journal of Advanced Research in Electrical, Electronics and Instrumentation engineering, vol.3, no. 3, March, 2014.
- [3] A. Salazar-Gonzales, D. Kaba, Y. Li, X. liu," Segmentation of blood vessels and optic disc in retinal images", IEEE Journal of Biomedical and Health Informatics 2014.