

# A Novel Approach for Bone Fracture Detection Using Image Processing

Dhiraj B. Bhakare<sup>1</sup>, Prajwal A. Jawalekar<sup>2</sup>, Sumit D. Korde<sup>3</sup>

<sup>1,2,3</sup>Department of Electronics & Telecommunication Engineering, Prof. Ram Meghe College of Engineering & Management, Bandera Road, Amravati (444602), Maharashtra, India

\*\*\*

**Abstract** - The computers have proved their usage in every sphere of our life including banking, online shopping, communication, education, research and development and including the field of medical science. In the field of medical sciences, there are a number of instruments and software's developed to help the doctors and the surgeons cure the patients by supporting them with high technical expertise. In this paper we are presenting a system, which is aimed to provide the orthopedic surgeons with the powerful tool. The traditional machine used to scan the X-ray and MRI reports gives the hazy picture about the bone part, which sometimes leads the surgeons to make wrong assumptions, and may henceforth lead them towards wrong diagnosis of the bone fractures. The software system developed here is equipping the orthopedic surgeons with the tool which is far much better in analyzing the X-rays and MRI scans than the traditional machines and the methods that the doctors have been using till now and can help them detect even multiple fractures with ease. This system works on the methods and algorithms developed to perform various operations on images, but these operations make life easy for the surgeons. The Image Processing is one field which is finding a lot of applications in today's world in the fields like seismology, remote sensing and medical and one example in the field of medical is this software system. Apart from that, there are a variety of software developed, which solely provide varieties of operations on images.

**Key Words:** X-Ray, Segmentation, Bone Fracture, Image Processing.

## 1. INTRODUCTION

Bones are the rigid organs in the human body which protect important organs such as brain, heart, lungs and other internal organs. The human body has 206 bones with various shapes, size and structures. The largest bones are the femur bones, and the smallest bones are the auditory ossicles. Bone fracture is a common problem in human beings. Bone fractures can occur due to accident or any other case in which high pressure is applied on the bones. There are different types of bone fracture occurs are oblique, compound, comminuted, spiral, greenstick and transverse. There are different types of medical imaging tools are available to detecting different types of abnormalities such as X-ray, Computed Tomography (CT), Magnetic Resonance Imaging (MRI), ultrasound etc. X-rays and CT are most frequently used in fracture diagnosis because it is the fastest and easiest way for the doctors to study the injuries of bones and joints. Doctors usually uses x-ray images to determine

whether a fracture exists, and the location of the fracture. The database is DICOM images. In modern hospitals, medical images are stored in the standard DICOM (Digital Imaging and Communications in Medicine) format which includes text into the images. Any attempt to retrieve and display these images must go through PACS (Picture Archives and Communication System) hardware.

### 1.1 Types of Fracture

The different types of fracture that can occur include:

1. Simple fracture – otherwise called closed fracture – This is caused when a broken bone does not penetrate the skin.
2. Open (compound) fracture – The bone breaks such that bone fragments project through the skin. This type of fracture is called open or compound fracture.
3. Hairline fracture – This type of fracture is occurring due to stress exerted in the foot or lower leg caused by activities such as jogging or running.
4. Greenstick fracture – This kind of fracture occurs when the bone bends and cracks. There is no breaking completely into separate pieces.
5. Complicated fracture – This fracture occurs when supporting bones surrounding the fracture are also damaged and injured. This may result in injury to the arteries.
6. Avulsion fracture – Muscles are anchored to the bone by structures called tendons. These are said to be a type of connective tissue. This type of fracture is more common in the knee and shoulder joints.
7. Comminuted fracture – In this type the bone is shattered into small pieces and this kind will take more time to heal.
8. Compression fracture – This type of fracture occurs when two bones are pressed against each other. can have this type of fracture. Aged people with osteoporosis have higher risk of developing this kind of fracture.

## 2. PROPOSED TECHNIQUE

### 2.1 Block diagram

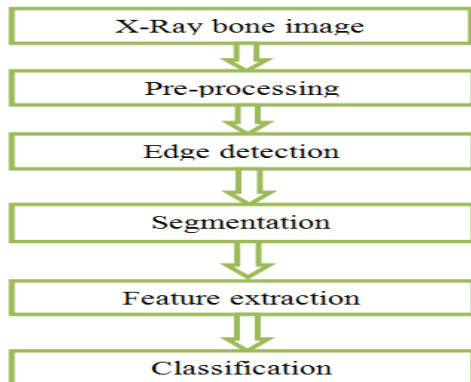


Fig.1. The flow diagram of steps in detecting the bone fracture in X-ray/CT images

#### Step 1: Preprocessing

These stages consist of the procedures that enhance the features of an input X-ray image so that the result image improves the performance of the subsequent stages of the proposed system.

#### Step 2: Edge Detection

It is based on analyzing the changes in the intensity in the image. However, the quality of edge detection is highly dependent on lighting conditions, the presence of objects of similar intensities, density of edges in the scene and noise. There are different algorithms for edge detections such as Canny, Laplacian and Sobel. In our experiments, the best results were obtained by using a modified version of the Canny edge detection algorithm in which the contrast is enhanced using a histogram equalization step. This finding is in accordance with the Nadernejad et al. result shows the results of using different edge detection algorithms.

#### Step 3: Segmentation

Image segmentation is the fundamental step to analyses image and extract data from them. It is an operation of partitioning an image into a collection of connected sets of pixels. The main purpose of interest in an image which helps in an image which helps in annotation of the object scene. There are three main approaches of image segmentation which are region approach, boundary approach, and edge approach.

#### Step 4: Image classifier

In this step different classifier is used like SVM (Support Vector Machine), K-Nearest Neighbor (KNN), Back Propagation Neural Network (BPNN), Nave Byes(NB).

#### Step 5: fracture detection

The last stage of this system is fracture detection it is performed by the procedures. First, the useful features

extracted from the image. And then, these features are used to detect fracture or non-fracture image

### 2.2 FLOWCHART

#### Description of Flowchart:

Here is an explanation of the performance of the system:

1. First user must input an image to be processed; the image will then be carried filtering to remove noise that exists in the image.
2. The next step will performed after image filtering process, the image will during Canny Edge method, it will give results more visible lines on an X
3. The system then check and combines the results of early detection canny with the Original image, then user can clearly see the shape of the bone and this combine will be processed by the system.
4. To detect the location of the fracture in the image, the system use shape detection with image matching process expressed when the line has an end, and give the result in percentage if and only if image will match with fractured image i. e. input x-ray image.
5. If image will not matched then no fractured will be detected.
6. Then final step is stop.

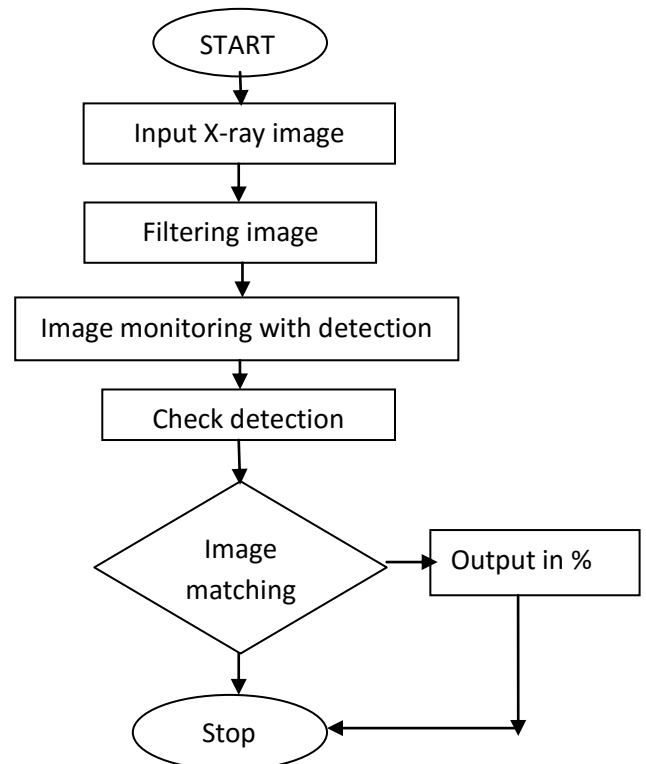


Fig.2.2 flow chart of system

### 3. CONCLUSIONS

A computer based analytical techniques for the detection of bone fracture using X-ray/CT images has been presented in this work which starts from the preprocessing to remove the noise and edge detected by using sobel edge detector. After the segmentation the area of the fracture is calculated. The method has been tested on a set of images and results have been evaluated. Analysis shows that results obtained are satisfactory and accuracy of this method was 85%.The limitation of this method is ,in CT and some cases of X-ray images very difficult to find the area of fracture, In future it is fully implemented to CT images and also classify the type of fracture is occurs.



Prajwal A. Jawalekar pursuing Final year in the year 2018. He is in Prof. Ram Meghe College of Engineering & Management, Bandera Road, Amravati in the department of Electronics & Telecommunication Engineering.



Sumit D. Korde pursuing Final year in the year 2018. He is in Prof. Ram Meghe College of Engineering & Management, Bandera Road, Amravati in the department of Electronics & Telecommunication Engineering.

### REFERENCES

- [1] Vijaykumar, V., Vanathi, P., Kanagasabapathy, P. (2010). Fast and efficient algorithm to remove gaussian noise in digital images. IAENG International Journal of Computer Science, 37(1).
- [2] Al-Khaffaf, H., Talib, A. Z., Salam, R. A. (2008). Removing salt-and-pepper noise from binary images of engineering drawings. In: Pattern Recognition. ICPR. 19th International Conference on, p. 1-4. IEEE.
- [3] Mahendran, S., Baboo, S. S. (2011). An enhanced tibia fracture detection tool using image processing and classification fusion techniques in X-ray images. Global Journal of Computer Science and Technology (GJCST), 11 (14) 23-28.
- [4] Chai, H. Y., Wee, L. K., Swee, T. T., Hussain, S. (2011). Gcm based adaptive crossed reconstructed (acr) k-mean clustering hand bone segmentation. p. 192-197.
- [5] Hao, S., Han, Y., Zhang, J., Ji, Z. (2013). Automatic isolation of carpal-bone in hand x-ray medical image. In Informatics and Management Science I, p. 657-662. Springer.
- [6] Bielecki, A., Korkosz, M., Zielinski, B. Hand radiographs preprocessing, image representation in the finger regions and joint space width measurements for image interpretation. Pattern Recognition, 41(12) 3786-3798, 2008.

### AUTHORS



Dhiraj B. Bhakare pursuing Final year in the year 2018. He is in Prof. Ram Meghe College of Engineering & Management, Bandera Road, Amravati in the department of Electronics & Telecommunication Engineering.