

# Lung Diseases Using Deep Learning: A Review Paper

Kinjal Prajapati<sup>1</sup>, Jigna Patel<sup>2</sup>, Ketki Pathak<sup>3</sup>

<sup>1,2</sup>Electronics and Communication Dept, Dr S&SS Ghandhy Govt. Engineering College, Surat, India

<sup>3</sup>Electronics and Communication Dept, Sarvajanik College of Engineering and Technology, Surat, India

\*\*\*

**Abstract** - The detection of abnormalities in the early stage is challenging and it aims to play a vital role in automated screening systems. Medical imaging modalities are used to probe the human body. Feature extraction is the most important step in image classification. It helps in extracting the feature of an images ideals possible. Feature extraction techniques are applied to get the feature that will be useful in classifying and recognizing the images. The proposed method have competitive results with comparatively shorter training time and better accuracy. The classifier are combined with the powerful feature extraction tool and principal components analysis and the evaluation of the performance is quite good over all the performance measures. The texture and shape features are estimate from the segmented region of interest.

**Key word:** lung diseases, deep learning, feature extraction.

## 1. INTRODUCTION

The lungs are pyramid-shaped, paired organs that are connected to the trachea by the right and left bronchi; on the under surface, the lungs are bordered by the diaphragm. The diaphragm is the flat, dome-shaped muscle located at the base of the lungs and thoracic cavity. The lungs are covered by the pleurae, which are attached to the mediastinum. The right lung is shorter and wider than the left lung. The **cardiac notch** is a dent on the surface of the left lung, and it allows space for the heart (Figure 1)<sup>[15]</sup>

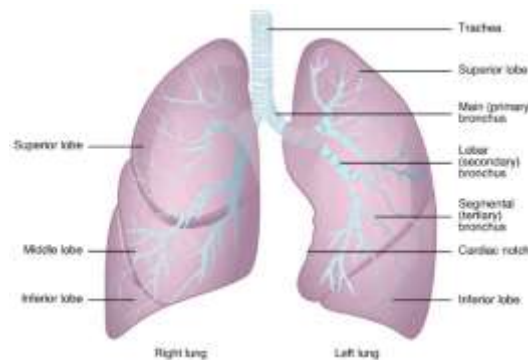


Fig -1 :lung anatomy<sup>[15]</sup>

## 2. LUNG DISEASES

The lung disease can include:

- ✓ Pneumonia
- ✓ Tuberculosis
- ✓ Sarcoidosis
- ✓ Idiopathic pulmonary fibrosis
- ✓ Interstitial lung disease
- ✓ Lung cancers
- ✓ Fibrosis caused by radiation
- ✓ Rheumatoid arthritis
- ✓ Infant and acute respiratory distress syndrome
- ✓ Inflammatory bowel disease (IBD)

## 2.1 Symptoms:

Most people with lung diseases have some symptoms, as in following:

- ❖ Shortness of breath
- ❖ Get enough breath
- ❖ A long-term cough, usually dry, Weight loss
- ❖ Chest pain
- ❖ Gasping breath
- ❖ Extreme exhaustion without a reason
- ❖ Depression

## 2.2 Tuberculosis (TB):

Tuberculosis (TB) is a major health concern nowadays. Among many infectious diseases, according to the 2017 WHO report [1] Tuberculosis (TB), caused by the continuing to increase due to burgeoning predisposing factors via infection with human immune deficiency virus, bacterial resistance to medication, large number of the homeless/drug users etc. The cause of TB's causative is Mycobacterium Tuberculosis which is designed for a rod, a non-spore that generates bacterial reeropic. Being a bacteria, the TB most closely affects lung cancer infections. Probably members such as lymphatics, pleura, bone and joints or meninges also affect the effect of other purmonic tuberculosis drugs.[1]

## 2.3 Detectable factors of TB:

Smoking is a major risk factor, which is growing throughout the world. Passive smoking is clinically active, and patients exhibited more positive TST results than non-exposed subjects (Kolappan and Gopi, 2002; Lin et al., 2007). Individuals living in the same house together Coughing in heavy smokers can be delayed by a TB diagnosis.[14]

## 2.4 Treatment:

Timely diagnosis and treatment is important for the patient morbidity and mortality, Tuberculosis diagnosis is 100% accurate for the gold standard test of culturing bacilli for 4 to 8 weeks for a definitive bacteriological diagnosis. However, TB still can be suspected among any asymptomatic individual that has no specific clinical symptom/or sign. Thus identifying a quick and efficient TB diagnostic tool is a major global public health priority. [14]

## 2.5 Diagnosis:

A detection of squamous cell carcinoma is through X-rays when there are any unusual abnormalities in the lungs. The some diagnostic methods are: 1. CT scan- The computed tomography of the chest aids pathologists visualize the lungs and vessels inside them through non-invasive imaging techniques. The technique involves injecting a dye known as contrast dye into the veins before scanning, so as to enable pathologists to clearly view the lungs. 2. PET Scan-Positron Emission Tomography test is a radiology test which is commonly used alongside other diagnosis measures like CT scan. 3. Bronchoscopy- A process in which large tube is inserted [14].

**1)chest X-RAY:** X-ray machine discharges radiation that goes into the body and imaging picture of the organs on the film. To diagnose lung cancer, x-ray imaging is used as step that helps in the identification of lung tumors. As mentioned, x-rays are not the final authority because they are unable to differentiate between the cancer and other lung diseases. Figure 2. [14]

**2)CT image:** CT scan stands for computed tomography, and it is an extended version of X-ray in which computer is attached to the X-ray machine. Pictures that are taken from taken angles and distances are processed in the computer and presented in the 3-dimentional, cross-sectional (tomographic) and in slices form. In this way, bones, tissues, blood vessels, and organs are shown up clearly. The imaging of CT scan is useful for diagnosis, treatment and progress of medication. Recently, helical or multi-slice scanning is introduced that almost eliminated gaps in the collection of slides. [14]

**3) PET scan (positron emission tomography scan):**If X-ray or CT scan diagnoses or doctor predicts any chances of lung cancer, PET scan is suggested for detailed results. In this imaging technique, tracer or radioactive glucose is injected and then scanners are rotating to take pictures which tissues or organs used tracer (Mac Manus et al., 2003). When malignant tumor cells use glucose, they are showing up brighter and more active in images. The integration of PET-CT scan is very useful for detecting the cancer. The CT scan gives a detailed view of tissues and organs, and PET gives pictures of abnormal activities and active cells. Researchers also concluded that PETCT scan are producing more accurate results as compared to PET or CT scan alone. [14]



Fig- 2: Chest X-RAY<sup>[15]</sup>

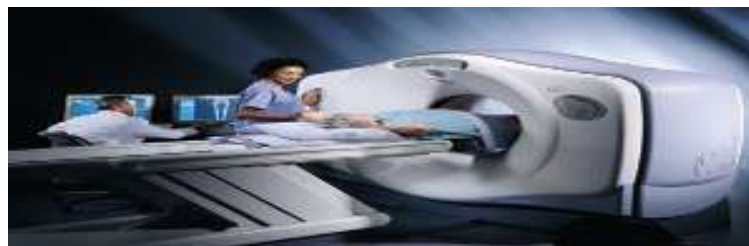

Fig- 3: CT scan<sup>[15]</sup>

### 3. LITERATURE REVIEW:

The TB objects are fed as input to the SVM learning algorithm of the MLP Neural Network (SVNN) and the result is compared with the state-of-the-art approach, Back Propagation Neural Network (BPNN). Results show that the segmentation method identifies the bacilli which retain their shape in spite of artifacts present in the images<sup>[4]</sup>

Computer-aided diagnosis used for detection of pulmonary TB at chest radiography used lung segmentation, texture and shape feature extraction, and classification with support vector machines to achieve an AUC of 0.87–0.90<sup>[7]</sup>

In <sup>[3]</sup> textural, focal, and shape abnormality subsystems are combined into one system to deal with the heterogeneous abnormality expression in different populations. The performance is on a TB screening and a TB open database using both an external and a radiological reference standard<sup>[3]</sup>.

In <sup>[6]</sup> this paper a method in which classify CXRs into two parts : TB and non-TB . based on methods in which shape, texture considered as feature then they combing and classified by classification like SVM,MLP,CNN.

A pyramid histogram of orientation gradients <sup>[7]</sup> using edge map, to automate pulmonary abnormality screening. To differentiate normal and abnormal CXR images using their corresponding thoracic edge first localize the relevant region of interest (ROI).

#### 3.1 Measurement parameter

$$\text{Sensitivity} = \frac{tn}{(tp+fn)} \quad (1)$$

$$\text{Specificity} = \frac{tn}{(fp+tn)} \quad (2)$$

$$\text{Accuracy} = \frac{(tp+tn)}{(tp+fn+fp+tn)} \quad (3)$$

### 3.2 Classification

Two main type of classifications are; unsupervised classification and supervised classification. Neural networks can be used to segregate data and have been produced in a more or less efficient manner. SVMs are effective machine learning techniques for classification and regression. Combine with regression estimation and linear operation inversion, the SVMs are capable of providing a novel approach to pattern recognition problems and can establish connections with learning theories of statistics.

A Support Vector Machine (SVM) is a discriminative classifier. Transforming the problem using some linear algebra does a linear SVM. This is where the kernel plays role.<sup>[16]</sup>

For **linear kernel** the equation for prediction for a new input using the dot product between the input (x) and each support vector (xi) is calculated as follows:<sup>[16]</sup>

$$\text{Kernel} = g(x) = A(0) + \text{sum}(ai * (x, xi)) \quad (4)$$

This is an equation that involves calculating the inner products of a new input vector (x) with all support vectors in training data. The coefficients A0 and ai (for each input) must be estimated from the training data by the learning algorithm.<sup>[16]</sup>

A schematic diagram of proposed method is as shown below.

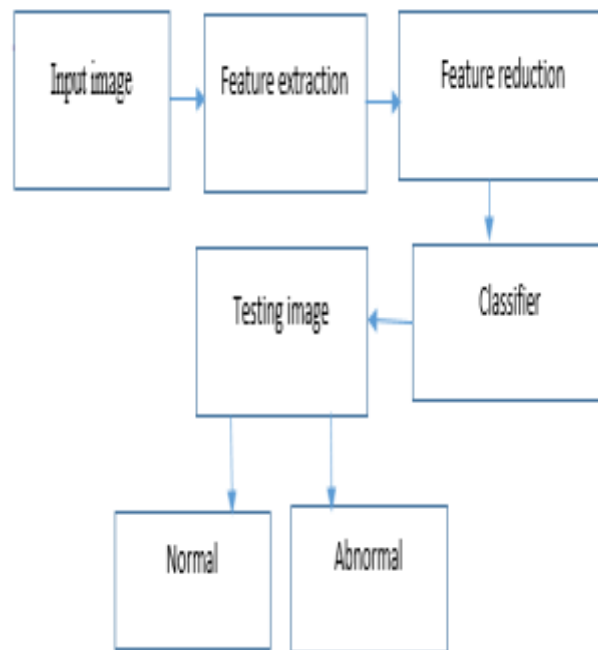


Fig- 4:Proposed block diagram

### 3.3 CNN (convolution neural network)

We have performed extensively and extensively in the field of deep convolutional neural networks (CNN) architecture, dataset characteristics, and transfer learning. We evaluate CNN performance on two different computer-aided diagnosis applications: thoraco-abdominal lymph node detection and interstitial lung disease classification. Based on evaluation, CNN model visualization, CNN performance analysis can be generalized to high performance CAD systems for other medical imaging tasks<sup>[17]</sup>

**Table No:1 Summery Table**

Paper	Summery	Research gap
Automated chest X-RAY screening. <sup>[2]</sup>	Automated chest X-Ray screening with lung region symmetry.	Develop methods to reliably highlight the regions
chest radiographs using a combination of textural, focal, shape abnormality analysis <sup>[3]</sup>	Proposed method which combines and detecting textural, shape, and focal abnormalities.	Improve the versatility of an automated detection system
classification of TB images using support vector neural network classifier <sup>[4]</sup>	Proposed methods in which normal and abnormal TB images detected.	Improve the classification accuracy considerably in both object and image level.
Abnormality recognition and feature extraction in female pelvic ultrasound imaging <sup>[5]</sup>	The texture and shape are extracted from the segmented ROI component. Give better outputs in a limited time frame.	Necessary to implementation with maximum number of input images
Feature Selection for Automatic Tuberculosis Screening in Frontal Chest Radiographs <sup>[6]</sup>	Proposed methods in which segmentation based on atlas based and shape ,texture feature were used.	Extract automatically features using an encoder type network.
Edge map analysis in chest X-rays for abnormality screening. <sup>[7]</sup>	Using edge map detection edges were detected.	Specialized methods for more than one feature
Chest radiographs Using Anatomical Atlases With Nonridged Registration <sup>[8]</sup>	Proposed methods detects lung boundaries, surpassing state-of-the-art performance as well as.	Improve the current benchmark evaluations for abnormal lung shapes.
Support Vector Machine Based Computer Aided Diagnosis System <sup>[9]</sup>	Support Vector Machine Based Computer Aided Diagnosis System with better accuracy	Develop technique to combine all features in one method.
Deep Learning vs. Bag of Features in Machine Learning <sup>[10]</sup>	feature extractor and image encoding techniques, in which highest classification accuracy for the Deep Learning approach in comparison with Bag of Features	The BoF image encoding with poor accuracy.

From this summery table we concluded that the CNN is best classifier among the different classifier .A deep learning approaches have highest accuracy than the bag of features .we can evaluate performances of parameter.

#### 4. DISCUSSION

There are many ways to diagnosis lung disease, such as Chest Radiograph (x-ray), Computed Tomography (CT), Magnetic Resonance Images (MRI Scan) and Sputum Cytology. First of all, multiple steps are involved in segmentation like; Image preprocessing, histogram analysis, threshold, morphological filling whether image is normal or abnormal. CNNs were explored to extract representative and discriminative features from X-ray images for classification in various body parts. The essential capability of CNN to capture the structure of the image in its feature maps.

Further improvements are available in the areas where the abnormalities lie, possibly through the use of deep learning algorithm, and the versatility of an automated detection system.

## 5. CONCLUSION

Lung disease is the most risky and overall in the world. Precise segmentation lung radiologist in the region of interest. To get more precise accurate result, we have to work out stages as shown in Figure 4. Stated with image enhancement, used histogram automatic thresholding method; Region growing different background from lung area. This method can be evaluated more effectively. For more accuracy we can used combine Multi-lay peptone, Support vector machine classifier.

## 6. REFERENCES

- [1] Global, W.H.O., 2018. tuberculosis report 2017. World Health Organization. Geneva.
- [2] Santosh, K.C. and Antani, S., 2018. Automated chest x-ray screening: Can lung region symmetry help detect pulmonary abnormalities?. *IEEE transactions on medical imaging*, 37(5), pp.1168-1177.
- [3] Hogeweg, L., Sánchez, C.I., Maduskar, P., Philipsen, R., Story, A., Dawson, R., Theron, G., Dheda, K., Peters-Bax, L. and Van Ginneken, B., 2015. Automatic detection of tuberculosis in chest radiographs using a combination of textural, focal, and shape abnormality analysis. *IEEE transactions on medical imaging*, 34(12), pp.2429-2442.
- [4] Priya, E. and Srinivasan, S., 2016. Automated object and image level classification of TB images using support vector neural network classifier. *Biocybernetics and Biomedical Engineering*, 36(4), pp.670-678.
- [5] Thampi, L. and Paul, V., 2018. Abnormality recognition and feature extraction in female pelvic ultrasound imaging. *Informatics in Medicine Unlocked*
- [6] Vajda, S., Karargyris, A., Jaeger, S., Santosh, K.C., Candemir, S., Xue, Z., Antani, S. and Thoma, G., 2018. Feature selection for automatic tuberculosis screening in frontal chest radiographs. *Journal of medical systems*, 42(8), p.146.
- [7] Santosh, K.C., Vajda, S., Antani, S. and Thoma, G.R., 2016. Edge map analysis in chest X-rays for automatic pulmonary abnormality screening. *International journal of computer assisted radiology and surgery*, 11(9), pp.1637-1646
- [8] Candemir, S., Jaeger, S., Palaniappan, K., Musco, J.P., Singh, R.K., Xue, Z., Karargyris, A., Antani, S., Thoma, G. and McDonald, C.J., 2014. Lung segmentation in chest radiographs using anatomical atlases with nonrigid registration. *IEEE transactions on medical imaging*, 33(2), pp.577-590
- [9] Mabrouk, M., Karrar, A. and Sharawy, A., 2013. Support vector machine based computer aided diagnosis system for large lung nodules classification. *Journal of Medical Imaging and Health Informatics*, 3(2), pp.214-220
- [10] Loussaief, S. and Abdelkrim, A., 2018, March. Deep learning vs. bag of features in machine learning for image classification. In *2018 International Conference on Advanced Systems and Electric Technologies (IC\_ASET)* (pp. 6-10). IEEE.
- [11] Elveren, E. and Yumuşak, N., 2011. Tuberculosis disease diagnosis using artificial neural network trained with genetic algorithm. *Journal of medical systems*, 35(3), pp.329-332.
- [12] Internal Clinical Guidelines Team (UK), Tuberculosis: Prevention, Diagnosis, Management and Service Organisation, National Institute for Health and Care Excellence, London, U.K., Jan. 2016. [Online]. Available: <https://www.ncbi.nlm.nih.gov/pubmed/22720337>
- [13] Shen, D., Wu, G. and Suk, H.I., 2017. Deep learning in medical image analysis. *Annual review of biomedical engineering*, 19, pp.221-248.
- [14] Gomathi, M. and Thangaraj, P., 2010. A computer aided diagnosis system for lung cancer detection using support vector machine. *American Journal of Applied Sciences*, 7(12), p.1532.
- [15] [https://opentextbc.ca/anatomyandphysiology/chapter/22-2-the-lungs/#fig-ch23\\_02\\_01](https://opentextbc.ca/anatomyandphysiology/chapter/22-2-the-lungs/#fig-ch23_02_01)