

# Optical Disc Detection, Localization and Glaucoma Identification of Retinal Fundus Image

Priya Hankare<sup>1</sup>, Purvi Kakasagar<sup>2</sup>, Bhaviya Jagad<sup>3</sup>, Dhwanil Barot<sup>4</sup>, Omkar Joshi<sup>5</sup>

<sup>2,5</sup>Department of Electronics and Telecommunications Engineering, K.J. SOMAIYA INSTITUTE OF ENGINEERING AND INFORMATION TECHNOLOGY, Mumbai, Maharashtra, India

<sup>1</sup> Assistant Professor, Department of electronics and Telecommunications, KJSIEIT, Mumbai, Maharashtra, India

\*\*\*

**Abstract** - The major cause of blindness in the world is diabetic-related eye disease. Various parts of the body get affected due to complication of diabetes. Diabetic retinopathy is termed as high level of glucose in the retina, which may cause blurring of the vision and can lead to blindness. To avoid further damage of vision, time to time testing of retina is done to detect the early stages of diabetic retinopathy. This project aims for detection of Diabetic retinopathy (DR) by taking cup to disc ratio into consideration. Morphological processing techniques are used on the fundus images to extract features of optic disc such as area of disc and area of cup, we calculate the area of each extracted feature. Depending on the area of cup to disc ratio we identify the severity of the disease. Depending on the severity of disease, treatment measures can be analysed. To make it more user friendly GUI in MATLAB is used and to track the progress of disease, database is maintained. By making use of this project, ophthalmologists will surely be able to track the severity of disease and make it more efficient to keep Diabetic retinopathy (DR) under control.

**KeyWords:** Diabetic Retinopathy(DR), Fundus Camera, Morphological Operations, Segmentation.

## 1. INTRODUCTION

In this project, an approach is made to identify the image given by the patient. The image is classified into 3 categories: Normal, Non-Proliferative Diabetic Retinopathy, Proliferative Diabetic Retinopathy. Processing of the fundus image is done so that various diseases in the eye can be obtained such as haemorrhages. Hard exudates, laser treatment marks, etc. Fundus camera has to be used for taking image of a retina. This process is useful for patients who cannot regularly visit doctor and thus sending an image of their retina will be useful for further diagnosis. This project aims to reduce the blindness caused due to diabetic retinopathy by regular scanning of the retina and processing it to determine the health of the eye.

## 2. LITERATURE SURVEY

An image processing system has the features to help the ophthalmologist in diagnosing eye diabetic retinopathy diseases better. It aims to detect the changes in retina. The classification system which states the DR stages are based on the values obtained of cup and disc. [1] The system can help ophthalmologist to perform early screening on diabetes patients. The proposed method used processes fundus image database obtained from Hospital. Together with other suitable retinal features extraction and classification methods, this segmentation method can form the basis of a fast and easy to use diagnostic support tool for diabetic retinopathy, which will give a huge advantage in terms of improved access to mass screening people for risk or presence of diabetes.

### 2.1 TYPES OF DISEASES: -

Microaneurysms -

The walls i.e. capillary walls are weakened which leads them to leakages.

Haemorrhages -

The capillaries that are weakened are ruptured which causes small dots or haemorrhages on the retinal layers. [2]

Exudates -

The proteins are leaked from retinal blood vessels. These look like yellow flakes. These are termed as hard exudates. These are the residues caused from leakage from damaged capillaries. The most common cause of hard exudates are DR [3].

Intraretinal Microvascular Abnormality (IrMA): -

Intraretinal microvascular abnormalities (or IrMAs) are the cause of dilation of blood vessels also known as capillaries within the retina. They appear as abnormal branching. [4]

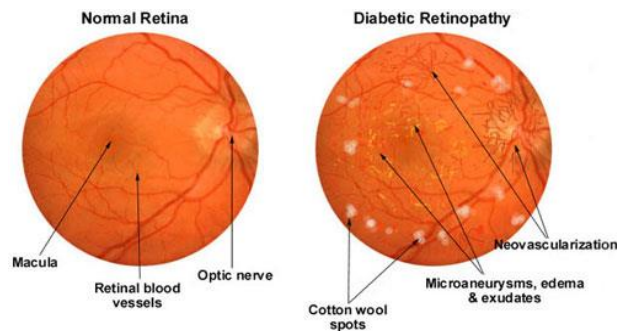


Fig 1: Healthy retina vs Diabetic Retinopathy affected eye.

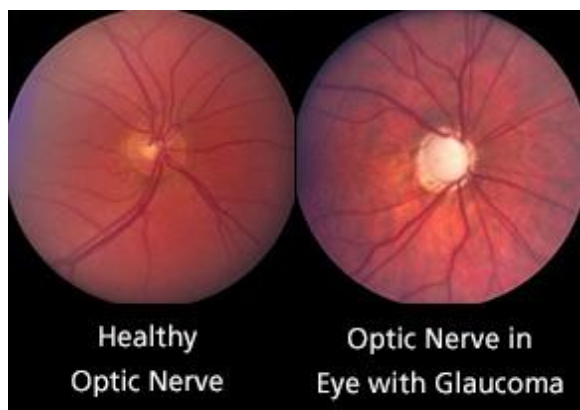


Fig 2: Healthy optic nerve vs optic nerve in eye with glaucoma

### 3. IMPLEMENTATION

Firstly, Fundus camera will be used to take images of retina. Retina images contains optical disc, blood vessels. This project is focused on optic disc. So the size of optic disc will be cropped and saved for further processing. The cropped image of optic disc will be converted into binary image. Then the cup of the disc will be cropped from the retina image. Same processing techniques will be used for the cup. The threshold levels of the two cropped images will be different. The ratio of cup-to-disc ratio is important for determining the severity of the disease. The ratio values can be different for various reasons but the range is majorly fixed for normal, mild or heavily DR affected eyes.

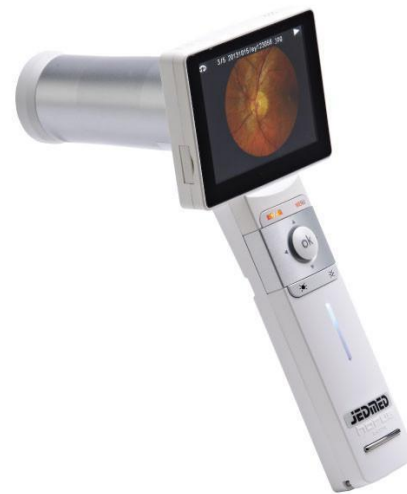
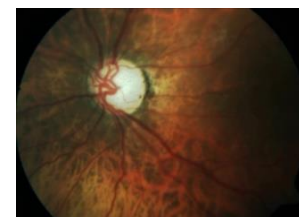
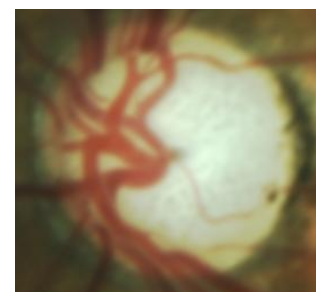
Fig 3: Handheld Fundus Camera

- Taking the image of retina by using fundus camera which has microscope attached to high end camera, back of the eye is captured.



Colour Image of Eye Effected by Glaucoma

- Then this captured image is transferred to the computer and is stored to maintain the database of patient.
- This retina image is colour image, we load this image into the application and then the optic disc is cropped manually.




Colour Image of Optic Disc

- We first detect the optic disc from the cropped image for which we make use of thresholding, i.e. we set threshold values for R, G and B.



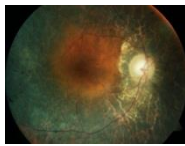
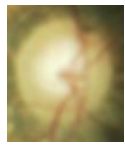



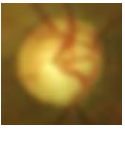


- Counting the black and the white pixels we get the area of the optic disc.
- Similarly, we set different thresholding value for cup and get the area of the cup.

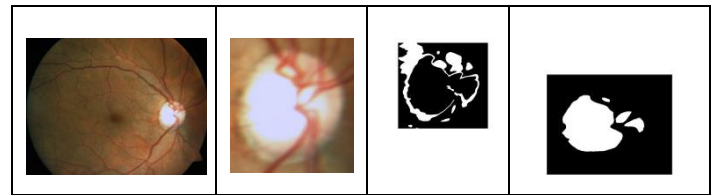


Binary Image of Cup

- By using this values of optic disc and cup, we find out the cup to disc ratio and depending on the value result is displayed, i.e. severity of the disease (HIGH, MEDIUM, NORMAL).

**4.RESULT & CONCLUSION**

Original	Cropped	Optic Disc	Cup
			
			



Early detection of diabetic retinopathy is very important because it enables timely treatment that can ease the burden of the disease on the patients and their families by maintaining a sufficient quality of vision and preventing severe vision loss and blindness. Positive economic benefits can be achieved with early detection of diabetic retinopathy because patients can be more productive and can live without special medical care. Image processing and analysis algorithms are important because they enable development of automated systems for early detection of diabetic retinopathy.

**ACKNOWLEDGEMENT**

We would like to thank Prof. Priya Hankare for her support and guidance. Also we would like to thank Aditya Jyot Hospital for their help in providing us retina pictures and solving all our queries.

**REFERENCES**

[1] Ahmad Zikri Rozlan ,Hadzli Hashim ,Syed Farid Syed Adnan ,Chen Ai Hong ,Miswanudin Mahyudin. “A proposed diabetic retinopathy classification algorithm with statistical inference of exudates detection”. IEEE Xplore.Web.11 September.2014

[2] Dr. Olivia Scott, “Diabetic Retinopathy and Diabetic Eye Problems”. Web.20 January 2016.

[3] Anonymous

[4] Chris Kirkpatrick, “Intraretinal Microvascular Abnormality (IrMA)”.2013



Purvi Kakasagar, Bachelor of Engineering from K.J. SOMAIYA INSTITUTE OF ENGINEERING AND INFORMATION TECHNOLOGY, Mumbai, Maharashtra, India



Bhaviya Jagad, Bachelor of Engineering from K.J. SOMAIYA INSTITUTE OF ENGINEERING AND INFORMATION TECHNOLOGY, Mumbai, Maharashtra, India



Dhwanil Barot, Bachelor of Engineering from K.J. SOMAIYA INSTITUTE OF ENGINEERING AND INFORMATION TECHNOLOGY, Mumbai, Maharashtra, India



Omkar Joshi, Bachelor of Engineering from K.J. SOMAIYA INSTITUTE OF ENGINEERING AND INFORMATION TECHNOLOGY, Mumbai, Maharashtra, India