

## A Review on MRI Based Automatic Brain Tumor Detection and Segmentation

<sup>1</sup>Asmita Ray, <sup>2</sup>Prof. Samir Kumar Bandyopadhyay

<sup>1</sup>Research Scholar, Department of Computer Science & Engineering, University of Calcutta,  
92 A.P.C. Road, Kolkata – 700009, India.

<sup>2</sup>Professor, Department of Computer Science & Engineering, University of Calcutta, 92 A.P.C. Road,  
Kolkata – 700009, India

### Abstract:

In medical image processing techniques detection of brain tumor from the MRI images plays a very challenging role. It considers as very powerful imaging technique which is capable to diagnosis the abnormalities in the brain compared to other medical imaging techniques such as X-ray, Computed Tomography (CT), Positron Emission Tomography (PET) etc. Experimental studies on MRI based brain tumor segmentation are getting more attention and coming closer to clinical acceptance as it provides non-invasive images with high resolution and excellent contrast between the different soft tissues of the body. Quality of brain images are affected by several problems like noise and partial volume effect due to overlapping tissues. These problems need to be addressed for accurate segmentation which is extremely important and essential for exact diagnosis by computer aided clinical tools. Different methods have been developed for segmentation of brain tumor efficiently. The most important application of segmentation technique is to isolate the tissue of the tumor part which includes active cells, necrotic core and edema from the normal part of brain tissues consisting of White Matter (WM), Gray Matter (GM), and Cerebrospinal Fluid (CSF). The purpose of this paper is to provide a comprehensive review of different brain tumor segmentation methods using MRI images by studying their advantages and disadvantages with earlier proposed segmentation techniques. Firstly, a brief introduction about brain tumors, their types and the reasons of brain tumor have been introduced. Then the comparison of different imaging modalities has been presented. Lastly a final assessment has been made by addressing the future developments and trends for MRI-based brain tumor segmentation methods.

**Keywords:** Brain Tumor, Magnetic Resonance Imaging (MRI), Segmentation, Necrosis, Edema White Matter, Gray Matter, Cerebrospinal Fluid.

### 1. Introduction

Brain has a very complicated anatomical structure. It consists of central nervous system that is considered to be the kernel part of the body. In recent years the anatomical study of human body and the treatment of different kinds of disease in distinct parts of the body show potential advancement depending on the medical imaging technology [1]. Brain tumor is one of the most common brain diseases. Brain tumor, occurs when abnormal cells form within the brain. Skull, is very rigid and it encloses the brain. So any growth inside such a restricted space increases pressure on the brain, as a result some brain tissues are shifted, pushed against the skull that cause of damage the nerves of the other healthy brain tissues [2].

Brain tumors can be cancerous (malignant) or non-cancerous (benign). Growth of benign or malignant tumors inside the skull cause of brain damage, and sometimes it can be life-threatening also. Therefore early detection of brain tumor is necessity for starting the treatment and saving life.

Rapid development of medical imaging technology and the introduction of various imaging modalities over the last few decades have transformed the medical image processing as one of the most emerging fields of this era. Medical imaging techniques play a crucial role for capturing the abnormalities of human body such as tumor, cancer, cyst, fibroid etc. Images are captured by different devices using different modalities such as X-ray, Computed Tomography (CT) Scan, Magnetic Resonance Imaging (MRI), Ultrasound, Positron Emission Tomography (PET), and Electrocardiogram (ECG). Among all the modalities MRI is the most efficient powerful tool to visualize the detailed and complete aspects of internal structures for accurate measurement of organ anatomy [3]. MRI medical imaging is non-invasive, provides high contrast between different soft tissues, high spatial resolution and also does not produce any harmful radiation. For these reasons MRI is widely used for detection, diagnosis and treatment of brain tumors. It is also able to provide the invaluable information regarding the tumor size, shape and localization without exposing the patient to a high ionization radiation [4]. It is also capable to produce images in axial, coronal and sagittal planes [3].

Medical image segmentation plays an important role in medical imaging applications. Image segmentation is the most important part in digital image processing. It divides a digital image into multiple regions in order to analyze them. The main objective of Image segmentation process is to subdivide an image into its constituent parts and extracts the parts of interest or

objects. Segmentation is a critical step of image analysis and its result is considerably depends on the accuracy of feature measurement [5].

In the year 2012 according to the statistical report of CBTRUS (Central Brain Tumor Registry of the United States) brain tumor is the second leading cause of cancer related deaths in children under age 20 and in males ages 20-39 (leukemia is the first) and the fifth leading cause of cancer-related deaths in females ages 20-39 [6].

Brain tumors are notoriously difficult disease to diagnose. 16,000 people each year are diagnosed with a brain tumor. Primary brain tumors occur in people of all ages but they are statistically more frequent in children and older adult. Metastatic brain tumors are common in adults than children. Every year 190,000 people in US and 10,000 people from Canada are diagnosed with a brain tumor. In 2015 an estimated 78,000 new cases were expected to be diagnosed with primary tumors of the brain and central nervous system and included nearly 25,000 primary malignant and 53,000 non-malignant brain tumors. In 2015, more than 4,600 individuals between the ages 0-19 will be diagnosed with a primary brain tumor. In United States 70,000 will be diagnosed with primary cancerous tumors of the brain and spinal cord. Based on statistics of 2015, nearly 17,000 people lost their live due to primary malignant and central nervous system brain tumor [7].

This paper presents a review of methods and techniques for detection of brain tumor through MRI image segmentation. The main objective of this paper is to focus on developing automated brain tumor detection and segmentation system which will assist to enhance the detection and visualization of brain tumors from the output of MRI scan.

## **2. Background**

### **2.1. Brain Morphology**

The decision and communication center of body is the nervous system. The central nervous system (CNS) is the part of the nervous system consisting of the brain and spinal cord. Together they control every part of daily life, from breathing and blinking to helping in memorizes the facts.

The brain is composed of three main parts forebrain, midbrain, and hindbrain. The forebrain consists of the cerebrum, thalamus, and hypothalamus (part of the limbic system). The midbrain consists of the tectum and tegmentum. The hindbrain is made of the cerebellum, pons and medulla. Often the midbrain, pons and medulla are together referred to as the brainstem.

**Cerebrum:** The largest part of the human brain is cerebrum or cortex, which is associated with higher brain function such as thought and action. The cerebral cortex is divided into four sections, called "lobes" the frontal lobe, parietal lobe, occipital lobe, and temporal lobe.

**Cerebellum:** Cerebellum is similar to the cerebrum, it has two hemispheres and has a highly folded surface or cortex. This structure is associated with regulation and coordination of movement, posture, and balance.

**Limbic System:** The limbic system, often referred to as the "emotional brain", is found buried within the cerebrum. This system contains the thalamus, hypothalamus, amygdala, and hippocampus.

**Brain Stem:** The "simplest" part of human brain is brain stem which underneath of the limbic system. This structure is responsible for basic vital life functions such as breathing, heartbeat, and blood pressure. The brain stem is made of the midbrain, pons, and medulla [8].

The brain is composed of two types of tissue, namely gray matter (GM) and white matter (WM). Gray matter is made of neuronal and glial cells, which is also known as neuroglia or glia that controls brain activity and the basal nuclei which are the gray matter nuclei located deep within the white matter. The basal nuclei is consists of caudate nucleus, putamen, pallidum and claustrum. Eminated axons which are the part of the white matter fibers connect the cerebral cortex with other brain regions. Corpus Callosum which is a thick band of white matter fibers connects the left and the right hemispheres of the brain. Both, cerebellum and cerebrum contain thin outer cortex of gray matter, internal white matter is small but deeply situated masses of the gray matter. The brain also contains cerebrospinal fluid (CSF) which consists of glucose, salts, enzymes, and white blood cells. For protection of brain and spinal cord from injury CSF circulates through channels (ventricles). Meninges are the membrane covering the brain and spinal cord [9].

### **2.2. Brain Tumor:**

Brain tumor is a mass or an abnormal growth of cells in brain or close to brain that includes cranial nerves, meninges, skull, pituitary gland, and pineal gland. This growth inside such a restricted space can disrupt proper function of brain and creates an increasing pressure in the brain. There are two main type of brain tumor: cancerous (malignant) or non-cancerous (benign). Cancerous tumors can be classified into two categories: primary tumor and secondary tumor [10].

**Primary Brain Tumor:** Primary brain tumor starts within the brain and usually do not spread to the other parts of the body. Primary brain tumors can be benign or malignant.

**Benign Tumor:** Benign tumors do not contain the cancer cell. These are least aggressive type of brain tumors and they are originate from cells within or surrounding the brain, they have slow growth rate, usually have distinct borders and rarely spread into other parts of body. They may become quite large before causing any symptoms and some of the primary tumors become progress to malignant. Removal of the entire tumor assured the fact of seldom grows back. Although its cells are not malignant, this tumor composed of benign cells and located in vital areas and can be considered as life-threatening.

**Malignant Tumor:** Malignant brain tumor contains cancer cell. They are likely to grow rapidly and crowd or invade the nearby healthy brain tissue. Malignant brain tumors are generally more serious and often life- threatening. Malignant brain tumors those are cancerous can spread within the brain and spine. They rarely spread to other parts of the body. These kinds of tumors are more common compared to primary brain tumors.

Malignant tumors do not have any clear border and due to this reason they have a tendency to send “roots” into nearby normal tissue. These tumors can be treated with surgery, chemotherapy and radiation, but they may recur after treatment.

**Metastatic (Secondary) Brain Tumor:** Cancer cells which are beginning to grow elsewhere in the body and spread to the brain is known as metastatic brain tumors. They form when cancer cells spread to the brain via the bloodstream. The most common cancers that spread to the brain are lung and breast.

All metastatic brain tumors are generally called as malignant and that can be truly known as “brain cancer”.

### 2.3. Brain Tumor Grading:

Doctors group brain tumors by grade to facilitate communication, plan treatment and predict outcomes [10]. The grade of a tumor not only refers to the way the cells look under a microscope but also indicates its degree of malignancy. Tumors often have a mix of cell grade and can change as they grow. Tumors are also classified by their cell type, which are usually taken during a biopsy, under a microscope. Cell type refers to the fact of origin of the tumor.

**Grade I:** Grade I tumors are the least malignant. They have an almost normal appearance when viewed through a microscope. Grade I tumors have slow growth rate and they are usually associated with long-term survival. For this grade of tumor surgery alone might be an effective treatment.

**Grade II:** Grade II tumors have a slightly abnormal microscopic appearance and are relatively slow-growing. Some can spread into nearby normal tissue and recur. Sometimes these tumors recur as a higher grade.

**Grade III:** Grade III tumors are malignant; a sharp distinction is not always visible between a grade II and a grade III tumor. The cells of the malignant tissue look very different from normal cells and are actively reproducing abnormal cells which grow into nearby normal brain tissue. These tumors tend to recur, often as a higher grade.

**Grade IV:** Most of the malignant tumors are considering as grade of IV. They tend to grow quickly; they can have a bizarre appearance when viewed under the microscope, and easily grow into surrounding normal brain tissue. These tumors form new blood vessels for maintaining their rapid growth. They also have areas of dead cells (necrosis) in their center.

Over time, lower-grade tumor might recur as a higher-grade tumor and this change happens more often among adults than children.

### 2.4 Brain Tumor Types:

Classification of the tumors have been performed by the standardize system of the World Health Organization (WHO). There are more than 120 types of brain tumors defined by the WHO based on cell origin, location and behavior [11]. A grade ranging from grade I (least malignant) to grade IV (most malignant) has been assigned to signify the rate of growth of different type of tumors. The most common primary tumor types found in adults are Gliomas, Meningiomas, Schwannomas, pituitary tumors, and CNS Lymphoma [12].

Within the malignant glioma group, the following subsets & WHO grades have been identified:

➤ Astrocytoma

- Pilocytic Astrocytoma (Grade I)
- Diffuse Astrocytoma (Grade II)

- Anaplastic Astrocytoma (Grade III)
- Glioblastoma multiforme (GBM) (Grade IV)
- Oligodendroglioma (Grade II)
  - Anaplastic Oligodendroglioma (Grade III)
- Ependymomas (Grade III)
  - Grade I Myxopapillary Ependymomas
  - Grade II Ependymoma
  - High-grade Anaplastic Ependymoma
- Mixed Oligoastrocytomas
- Others (Meningiomas , Schwannomas, Craniopharyngiomas, Germ Cell, Pineal Region, CNS lymphoma)

The most common brain tumors are gliomas, which originate in the glial (supportive) tissue. Gliomas reside within the substance of the brain and often intermix with normal brain tissue so they called intrinsic brain tumors. There are different grades of gliomas like "low-grade" or "high-grade" gliomas. The low or high grade designation represents the growth potential and aggressiveness of the tumor. There are several types of gliomas, including the following: astrocyte, oligodendrocyte, ependymomas. Occasionally, tumors will display a mixture of these different cells and are called mixed gliomas.

**Astrocytomas:** Astrocytomas arise from small, star-shaped cells called astrocytes. In adults, astrocytomas most often arise in the cerebrum. But they may grow anywhere in the brain or spinal cord. In children, they occur in the brain stem, the cerebrum, and the cerebellum. A grade III astrocytoma is usually called anaplastic astrocytoma. A grade IV astrocytoma is sometimes called glioblastoma multiforme.

Most common early symptoms of astrocytoma are memory loss, headaches, seizures, and changes in behavior. Other symptoms are depended on the two main factors like size and location of the tumors.

**Oligodendrocyte:** Oligodendrocyte arises in the cells that produce myelin, the fatty covering that protects nerves. These kinds of tumors usually arise in the cerebrum. They grow slowly and usually do not spread into surrounding brain tissue. The most common symptoms are headaches, personality changes, and seizures. Other symptoms vary with location and size of the tumor.

**Ependymal:** Ependymal develops in the cells that form the lining of the fluid cavities in the brain. They may appear in the different locations within brain and spinal cord. Although these tumors can develop at any age, they are most common in childhood and adolescence. Ependymomas are usually soft, grayish, or red tumors which may contain cysts or mineral calcifications.

Symptoms of an ependymal may occur depending on the size and location of the tumor. Increasing the head size may be one of the first symptoms in case of babies. In older children and adults, nausea, vomiting, and headache are the most common symptoms.

**Glioma (also called Oligoastrocytoma):** Mixed gliomas are brain tumors that contain more than one type of cell. These tumors usually contain a high proportion of more than one type of cell, most often astrocytes and oligodendrocytes. Sometimes, ependymal cells are also found. These tumors can be found anywhere within the cerebral hemispheres of the brain, although frontal and temporal lobes are the most common locations.

Oligoastrocytomas (grade II) are considered as low-grade tumors. They have slower growth rate than anaplastic oligoastrocytomas (grade III), which are malignant. Oligoastrocytomas may evolve over time into anaplastic oligoastrocytomas. Oligoastrocytomas develop in young and middle-aged adults' (ages 30 to 50). In case of children it is diagnosed at very fewer rates.

The most common symptoms of these tumors are seizures, headaches and personality changes. Other symptoms depend on the location and size of the tumor.

There are other types of brain tumors that do not begin in glial tissue. Some of the most common are described below:

**Meningiomas:** Meningiomas are usually benign tumors and grow from the meninges. Brain may be able to adjust to their presence due to the slow growth rate. Meningiomas may grow quite large before they cause symptoms. They occur most often in women between 30 and 50 years of age.

**Schwannomas:** Schwannomas arise from Schwann cells; they are benign tumors which produce the myelin that protects peripheral nerves. Acoustic neuromas are a type of schwannoma. Adults are mainly affected by these types of tumors. These tumors mainly occur in women twice as often as men.

**Craniopharyngiomas:** Craniopharyngiomas develop in the region of the pituitary gland near the hypothalamus. They are usually benign tumors but sometimes they are considered malignant because they can press on or damage the hypothalamus and affect vital functions. These tumors occur most often in children and adolescents.

**Germ Cell Tumors:** Germ cell tumors arise from primitive (developing) sex cells, or germ cells. The most frequent type of germ cell tumor in the brain is a germinoma.

**Pineal region tumors:** Pineal region tumors occur in or around the pineal gland, a tiny organ near the center of the brain. The tumor can be slow growing (pineocytoma) or fast growing (pineoblastoma). The pineal region is very difficult to reach, and these tumors often cannot be removed.

**Primary central nervous system (CNS):** Primary central nervous system (CNS) lymphoma is a disease in which malignant (cancer) cells form in the lymph tissue of the brain and/or spinal cord or eyes. Treatment commonly includes chemotherapy and/or radiation [13].

### 2.5 Reasons and Symptoms of Brain Tumor:

Medical Science unable to find out the reason of brain tumor occurrence and it is also incapable to prevent the primary tumor that start in the brain.

Different symptoms of brain tumor are related to the functional area of the brain and it helps the doctor by providing the clues of tumor location [14].

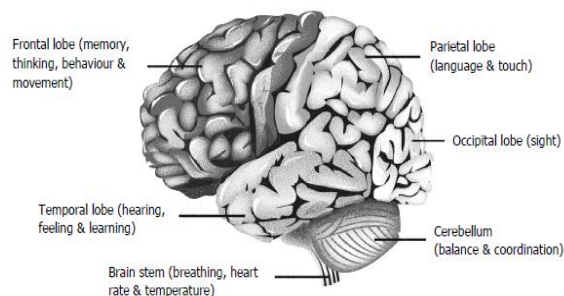


Fig 1: Lobes of brain and their functions

Fig1 shows the lobes of brain and their functions. Symptoms of brain tumor may vary with the different lobe of the brain. Lobes with their symptoms are as follows:

Frontal Lobe tumors may cause

- Vision loss
- Memory loss
- Impaired judgment
- Impaired sense of smell
- Reduce mental abilities
- Behavioral and emotional changes
- Paralysis on one side of the body

Parietal Lobe tumors may cause

- Lack of recognition
- Impaired speech
- Inability to write
- Spatial Disorder

Occipital Lobe tumor may cause

- Vision loss in one or both eyes

Temporal Lobe tumor may cause

- Memory difficulty
- Impaired Speech

Pituitary gland tumor may cause

- Abnormal secretion of milk
- Decreased libido
- Increased hormones secretion
- Stop of menstruation

Brainstem tumor may cause

- Hearing loss
- Drowsiness
- Vomiting
- Double vision or drooping eyelid
- Changes in behaviors and in emotions
- Weakness of the muscle on one side of the body
- Weakness of the muscle on one side of the face (like head tilt, crooked smile)
- Difficulty in speaking and swallowing
- Uncoordinated gait

### 3. Scan and Imaging Techniques

There are different kinds of brain imaging techniques are available for investigating the disorders insider brain without invasive neuro- surgery. A snapshot of brain is obtained from those techniques which help the neuroscientists to locate the affected area of the brain with neurological disorder from the other parts.

Most commonly used brain imaging techniques are discussed below [15].

- **Computed Tomography (CT):** Computed Tomography or computerized axial tomography scan (CAT scan) which is also called CT scan uses x-ray for detecting variety of disease by producing the cross sections of the body. It produces multiple numbers of pictures of the body and cross sectional images have been reformatted in multiple planes, three dimensional images are also generated by it. More details can be obtained from CT images of internal organs, bones, soft tissue and blood vessels compared to traditional x-ray.  
The advantages of CT images are (a) it is painless, noninvasive and accurate, (b) it is fast, simple; in emergency situation it helps to save life by detecting stroke area, internal injuries and bleeding, (c) exploratory surgery and surgical biopsy may be reduced due to the diagnosis which is determined by CT scanning.  
Delivery of high dose of radiation is the main drawback of CT scan.
- **Magnetic Resonance Imaging (MRI):** Magnetic Resonance Imaging also known as Nuclear Magnetic Resonance (NMRI) or Magnetic Resonance Tomography (MRT) which is used in radiology for investigating the anatomy and physiology of the body in both health and disease. Magnetic fields, radio waves and field gradients are used in MRI scanner to form images of the body. It is highly versatile imaging technique which mostly used in diagnostic medicine and biomedical research due to of its better resolution than CT. In clinical practice MRI is used to distinguish the pathological tissue (brain tumor) from the normal tissue. The main advantage of MRI scan is, it is harmless to the patient as it does not use any ionizing radiation. Brain tumors, spinal infections, bone tumors, multiple sclerosis etc. can be diagnosis very well due to of its excellent contrast details. It Is very expensive due to high cost of the

equipment. In presence of foreign bodies and metallic implants like pacemaker, aneurysm clips etc MRI cannot be performed.

- **Functional Magnetic Resonance Imaging (fMRI):** Functional Magnetic Resonance Imaging (fMRI) procedure using MRI technology and by measuring the brain activity changes in blood flow is detected by this technique. Blood flow occurs in response to neural activity. When the area of the brain is more active then the blood flow to that region is increased. The primary form of fMRI uses the blood-oxygen- level-dependent (BOLD) contrast, it is used to produce the activation maps to show which parts of the brain are involved in a particular mental process. It is non invasive and does not involve radiation. It is easy for experimental use and also has excellent spatial and temporal resolutions. The main disadvantage of this technique is it is very expensive.
- **Positron Emission Tomography (PET):** Positron Emission Tomography (PET) is a nuclear medicine and functional imaging technique, metabolic process in the body has been observed by this technique. It is used in both medical and research field. It is mostly used in clinical oncology and for diagnosis of certain diffuse brain disease such as dementias. There are various advantages of PET which are: (a) PET is very powerful imaging technique for studying metabolic functions of patients and the study of these functions is able to establish PET imaging as an alternative of biopsy and other exploratory surgeries to determine how much a disease has spread, (b) it is more accurate and extremely useful medical tool which has the ability to distinguish between benign (non-cancerous) and malignant (cancerous) tumors.  
Despite of various advantages of PET imaging, it contains some disadvantages that include: PET scan has risk caused by the radioactive component which has been used during this procedure and this kind of imaging is expensive also.

#### 4. Brain Tumor Segmentation Methods:

The purpose of this study is to automatic segmentation of the brain tumor region from the MR images which overcome the process of time taking manual segmentation of large data sets. This paper includes various methods for image segmentation such as Thresholding, Region Growing, Edge Detection base Method, Clustering, Classifier, Atlas-Guided Approach, and Deformable Model Methods. Among these thresholding and region growing are the conventional methods for brain tumor segmentation which are commonly employed in two-dimensional image segmentation.

**4.1. Thresholding:** Thresholding is a simplest, effective segmentation method easy to accomplish. In thresholding approach, image segmentation depends on gray level intensity value of pixels. In histogram thresholding method image is divided into two equal halves and to detect the tumor, histograms are compared and to find a proper physical dimension of brain tumor cropping method is used. Histogram of image is consists of peaks and valleys, where each peak represents one region. Threshold value is represented by the valley between the peaks.

Threshold-based methods are classified into two i.e. global and local thresholds. In Global thresholding method, the object of an image has the homogeneous intensity and high contrast between foreground and background and only one threshold value is selected for the entire image. It is simple and takes less computation time only if the image has homogeneous intensity. Threshold selection will become difficult when the contrast of an image is low. It is used for bimodal images. Global thresholding is likely to fail if the background illumination is uneven [16].

In local thresholding, firstly an image is divided into sub-images, then threshold values are selected locally and a threshold value is calculated for each part. More computation time has been taken by local thresholding method than global thresholding. It can extract only small regions and its result is satisfactory in background variations in an image. In local thresholding, multiple thresholds are used to compensate the uneven illumination [17]. In thresholding approach pixel information is the most vital part for making decision. In thresholding, basic shape of an image has been extracted by overlooking the little unnecessary details.

**4.2. Edged Detection Based Method:** Edged Based Segmentation is the most common method and it is basically used for contour detection. This technique partition an image based on discontinuities in gray level, color etc and often these edges represent the boundaries between objects [18,19]. Edges based segmentation can be classified into two categories such as (a) gray histogram, (b) gradient based method [20].

The result of edge detection technique mainly depends on selection of threshold value [20]. Gradient based method mainly focuses the difference between two neighboring pixel values. Edge detection operators which are commonly used in gradient based method are sobel operator, canny operator, Laplace operator, Laplacian of Gaussian (LOG) operator [18].

Edge detection method works well for those images which have good contrast between object and background, desire result cannot be obtained for images with smooth transition and low contrast. Edge of a region can often be hard to find because of noise or occlusions.

**4.3. Region Growing:** Region-based segmentation methods examine pixels in an image and disjoint regions are formed by merging neighborhood pixels with homogeneity properties based on a predefined similarity criterion [21]. The region growing and the watershed segmentation methods are part of the region-based methods and they are mostly used in the process of brain tumor segmentation. It is a simpler segmentation method and in this method connected region of similar pixel is extracted from an image [22]. It starts with some initial seed point (pixel) selection using some predefined criteria. Neighbors of the seed are checked and add them to the region based on similarity criteria satisfying by the pixel. Similarity criteria of a region depending on any characteristic of the region in the image: texture, color or average intensity. Manually or by an automatic seed-finding procedure are the two procedures for detection of seed [23]. The procedure iterates until no more pixels can be added to the region. Region growing methods can correctly separate the regions that have the same properties. This method can provide good segmentation results if the original images have clear edges. Small numbers of seed point is required to represent the desire property and then grow the region. It performs well with respect to noise [24, 25]. According to the researchers region growing is an effective approach and less computation intensive than other non-region-based methods for segmenting MRI images of brain tumors, especially for the homogeneous tissues and regions [26, 27]. The partial volume effect [28] is the fundamental disadvantage of region growing method by which the accuracy of MRI brain image segmentation has been restricted. This type of effect is responsible for blurs the intensity distinction between different tissue classes at the border of the two tissues types, because more than one kind of tissue types may be represented the voxel [29]. Region growing process is incorporated as a refinement step by some segmentation methods [30]. Automatic segmentation of brain tumor using MRI images has been performed by the proposed fuzzy information fusion framework [31]. The registration of multispectral images was the first step for the creation of this framework including a priori knowledge, fuzzy feature fusion, and an adjustment by fuzzy region growing.

Splitting process is the process where region get divided into sub regions that do not satisfy a given homogeneity criteria. Splitting and merging can be used together and their performance depends on the selected homogeneity criterion. Seed can be selected automatically or manually in region growing method. Their automated selection is based on the finding pixels that are the key interest, e.g. the brightest pixel in an image can considered as a seed pixel. Peaks found in an image histogram are also used to determine them. Manual selection of the seed has also been performed for every object present in the image. In this method, a set of seeds are used to segment an image into different regions. Each seeded region is represented by a set  $S$  and it is a connected component comprising of one or more points. The set of immediate neighbors bordering the pixel is calculated. The neighbors are then assessed to determine if the intersection of any region of set  $S$  has been taken place or not, if intersection is performed then a measure  $\delta$  (difference between a pixel and the intersected region) is computed.

If the neighbors intersect more than one region, then the set is taken as that region for which difference measure  $\delta$  is maximum. The new state of regions for the set then constitutes input to the next iteration. This process continues until the entire image pixels have been assimilated into regions [32]. To make the method automatic by eliminating the dependency on initial seeds statistical information and a priori knowledge can be incorporated in the algorithm. An image is partitioned in edge method using frequent changes in intensity near the edges, while, region method divide an image into regions which are similar as per a set of predetermined criteria [33].

Multi-scale watershed transformation is used by some researchers to segment brain tumors [34, 35]. Watershed algorithm is used to capture weak edges and also useful to identify the foreground and back ground of the image. In water segmentation, an image considers as a surface where bright pixels are represented as mountain tops and dark pixels are represented as valleys. Some valleys have punctures which are slowly merged into water that will be poured and then it will start to fill the valleys. The water is not allowed to be mixed if it is comes from different punctures. So, the dam is developed as contact points which make dams work as boundaries of water and image objects [36]. An analysis of user-assisted hierarchical watershed segmentation methods of brain tumors from MRI data was performed [37]. The watershed segmentation methods usually suffer from over-segmentation. To overcome the effect of severe over-segmentation and produce a reasonable segmentation, some advanced methods have been proposed [38-40].

Most of the brain tumor segmentations have been performed based on the clustering or classification methods such as Fuzzy C-Means (FCM), K-Means, Markov Random Fields (MRF), Bayes, Artificial Neural Networks (ANN), Support Vector Machines (SVM), Atlas-Guided Approach etc. In this section, FCM, K-Means, Atlas-Guided Approach, K-NN, SVM and Deformable Model Methods for segmenting brain tumor have been discussed.



**4.4. Clustering Based Methods:** Clustering is the unsupervised classification of patterns based on some feature, attribute and characteristic into groups (clusters). A cluster consists of groups of similar objects. There are two types of clustering, supervised and unsupervised. Cluster criteria are specified by the user in supervised type clustering. In unsupervised clustering cluster criteria are decided by the clustering system itself.

- (a) **K-Means Clustering:** K-Means is one of the popular partitioning algorithms. This procedure follows a simple and easy way to classify the data into k clusters where k is the input parameter specified in advance through iterative relocation technique which converges to local minimum. The purpose of this algorithm is to minimize the distances of all the elements to their cluster centres. It consists of two separate phases, first phase is to determine k centers at random one for each cluster. Next phase is to determine distance between data points in dataset and the cluster centers and assigning the data point to its nearest cluster. Euclidean distance is generally considered to determine the distance. When all the data points are included in some clusters an initial grouping is done. New centers are then calculated by taking the average of points in the clusters.

Automation of detection and segmentation of brain tumors in MRI images is a very challenging task due to occurrence of high degree of gray-level similarity in the image. A fully automated two-step segmentation process of brain MRI images has been proposed by T. U. Paul and S. K. Bandhyopadhyay [41].

- (b) **Fuzzy C-means (FCM):** In many situations, it is difficult to determine whether a pixel belongs to a region or not due to the unsharp transitions at region boundaries. Fuzzy concept has been proposed by Bezdek [42] to address this problem and is frequently used in pattern recognition. This method divides one group of data into two or more clusters. In this technique, membership to each data point has been assigned corresponding to each cluster center on the basis of distance between the cluster and the data point. The advantages of FCM algorithm include: (a) Gives best result for overlapped data set and it produces better result compare to k-means algorithm, (b) Unlike k-means where data point must exclusively belong to one cluster center, here data point is assigned membership to each cluster center as a result of which data point may belong to more than one cluster center. Encouraging result can be obtained by using of FCM in to MR data set [43]. Application of FCM for segmentation of brain tumor is becoming a fruitful research area. Since FCM is an iterative algorithm, it is considered as a very time consuming clustering method. In order to reduce the execution time of this algorithm, some solutions such as Fast Generalized FCM (FGFCM) clustering algorithms and Bias-Corrected FCM (BCFCM) algorithm have been proposed. FGFCM clustering algorithm is introduced for brain tumor segmentation by incorporating local information [44]. BCFCM provides a good result for segmentation of brain images in a very quick way that representing it as an excellent tool to support virtual brain endoscopy to realize the segmentation of brain tumor [45].

**4.5. Atlas-based algorithms:** Atlas based algorithms are very powerful tool which are used to segment the medical image based on the availability of standard atlas or template. Atlas is generated by compiling the information and this segmentation approaches have been widely used for brain tissue segmentation. The steps which are generally used in Atlas-based algorithms to segment the brain tumor: firstly, an affine registration which is used to brings the atlas and the patient into global correspondence; secondly, a template for the brain tumor has been developed by the seeding of a synthetic tumor into brain. Atlases had been used by researchers not only to impose spatial constraints, but also to provide probabilistic information about the tissue model.

Some techniques for construction of atlas have been described by Rohlfing et al. [46] and explored in more details by the other researcher [47] where the strategies for the atlas selection have been presented. A major challenge associated with atlas-based segmentation techniques is developing the atlas itself. Atlases have broad application in medical image segmentation and registration and are often used in computer aided diagnosis to measure the shape of an object or detect the morphological differences between patient groups. Various techniques for atlas construction are developed for different human organs, like the heart [48-50] and especially the brain [51-60]. Currently some atlases such as Brodmann, Talairach Tournoux, BrainWeb, and Whole Brain have been used.

**4.6. Classification Methods:** Machine learning potentially reduce the burden on radiologists by providing an automated analysis and diagnosis for medical images [61] that is capable to learn complex relationships or patterns from empirical data and make accurate decisions [62].

Machine learning algorithms can be divided into different categories based on different principles. This method is classified into supervised learning, semi-supervised learning, and unsupervised learning algorithms based on the utilization labels of

training samples [63]. In Supervised learning, each sample is organized into two different parts: One is input observations or features and the other is output observations or labels [64]. The main objective of this type of method is to deduce a functional relationship from training data that generalizes well to testing data. Classification algorithm is a representative method of the supervised learning.

In unsupervised learning only one set of observations are available and there is no label information for each sample [65]. The main aim of unsupervised learning is to recognize the relationships between samples or reveal the latent variables behind the observations. Clustering algorithm is a representative method of the unsupervised learning. Semi-supervised learning is consists of by combining the supervised and unsupervised learning [66].

**(a) K-Nearest Neighbor (K-NN):** The K-Nearest Neighbor classifier is a conventional non-parametric classifier that provides good performance for optimal values of  $k$ . It is simplest among all machine learning algorithms. In K-NN classification, the output is considered as a class membership. Classification of an object can be done by a majority vote of its neighbors, with the object being assigned to the class most common among its  $k$  nearest neighbors ( $k$  is a positive integer, typically small). It depends on the value of  $k$ , if the value is  $k = 1$ , then the object is simply assigned to the class of that single nearest neighbor. This algorithm based on a distance function and Euclidian distance has been used to calculate the K-Nearest Neighbor. The  $k$ -NN has higher accuracy and stability for MRI data than other common statistical classifiers, but has a slow running time [67].

**(b) Support Vector Machine (SVM):** Support Vector Machine (SVM) is a supervised classifier with associated learning algorithms. It is mainly derived from statistical theory [68, 69]. It has great classification ability and due to this property it is used widely in the field of brain tumor segmentation [70-74]. SVM takes a set of input data and predicts for each input data those are given, possible classes of output are formed that making it a non-probabilistic binary linear classifier. SVM can also be treated as non-linear classification which using kernel. There are many kernel functions such as linear, polynomial of degree and Radial basis function (RBF). Radial basis function is mainly used among all functions in MRI brain images [75]. In this research work, MRI images have been classified using SVM into two separate classes such as abnormal and normal by many authors [76-79]. This method is better with comparison of rule based system but accuracy of this method is low.

**4.7. Deformable Model Methods:** Medical images are often corrupted by noise and sampling artifacts, which can cause considerable difficulties when applying classical segmentation techniques such as edge detection and thresholding. Either these kinds of techniques fail completely or require some kind of post-processing step to remove invalid object boundaries in the segmentation results. To overcome these difficulties, deformable models have been extensively studied and it is also used widely in medical image segmentation, with promising results. The main purpose of this technique is to segment the volumetric (3D) image data. Although the term deformable models had been first appeared by Terzopoulos and his collaborators in the late eighties [80–83], the idea of deforming a template for extracting image features dates back much farther, to the work of Fischler and Elschlager's spring-loaded templates [84] and Widrow's rubber mask technique [85]. Similar ideas have also been proposed in the work by Blake and Zisserman [18], Grenander et al. [86], and Miller et al. [87]. Deformable models have grown to be one of the most active and successful research areas in image segmentation. Different names have been used in the literature to refer the deformable model such as snakes, active contours or surfaces, balloons, and deformable contours or surfaces. There are basically two types of deformable models: parametric deformable models [88, 89-91] and geometric deformable models [92-95].

Parametric deformable models represent curves and surfaces explicitly in their parametric forms during deformation. Direct interaction with the model has been allowed by this representation and can lead to a compact representation for fast real-time implementation. It is difficult to perform splitting and merging parts during deformation using parametric model.

On the other hand, geometric deformable models, capable to handle topological changes naturally. These models, based on the theory of curve evolution [96-99] and the level set method [100, 101], represent curves and surfaces implicitly as a level set of a higher-dimensional scalar function. After performing the complete deformation, their parameterizations have been computed, thereby allowing topological adaptivity to be easily accommodated.

## 5. Conclusion and Outlook

A critical review for MRI based tumor segmentation methods have been provided by this article. In this paper a comparative study of various automated techniques with their merits and demerits for detection and segmentation of brain tumor from

MRI images have been made. In past several decades many image segmentation algorithms have been developed, but still it remains a challenging task. A segmentation method which may perform well for one MRI brain image but it is not assured that it will produce same result for other MRI image of similar type. Achieving a generic segmentation method that can commonly use for all MRI brain images is very much difficult. Thus a general conclusion for the different segmentation methods with respect to the accuracy, validity and the robustness cannot be drawn and also cannot be compared directly with each other as the methods are evaluated depending on different data sets. The main purpose of all methods is to locate the tumor from MRI images in an efficient, accurate and reproducible way. Most of brain tumor segmentation algorithms have provided relatively good results but due to lack interaction between researchers and clinicians, clinicians still rely on manual segmentation for brain tumor in many cases. Robustness is one of the major assessment criteria for brain tumor segmentation. In some cases, failure of automatic segmentation technique loss the trust of the clinicians and this fact is also the cause of unacceptability for the future use. This paper also presents the most commonly used radiological modalities for imaging anatomy. With the development of these modalities it has been easy to localization the different areas of the brain tumor. Advancement of the studies in the area of automatic brain tumor segmentation has provided the potentiality for better prognostic information and optimization for the advantageous treatment options.

**References:**

- [1] M. P. Gupta and M. M. Shringirishi, "Implementation of brain tumor segmentation in brain mr images using k-means clustering and fuzzy c-means algorithm", International Journal of Computers & Technology, vol. 5, no. 1, 2013, pp. 54-59.
- [2] Charles R. Noback, Norman L. Strominger, Robert J. Demarest and David A. Ruggiero, "The Human Nervous System: Structure and Function", 6th edition, 2005, Humana Press.
- [3] R. Damadian, "Tumor Detection by Nuclear Magnetic Resonance", Science, New Series, vol. 171, Mar.1971, pp.1151-1153.
- [4] Z.-P. Liang and P. C. Lauterbur, "Principles of Magnetic Resonance Imaging: A Signal Processing Perspective", 1999, Wiley-IEEE Press.
- [5] N. R. Pal and S. K. Pal, "A Review on Image Segmentation Techniques", Pattern Recognition, vol. 26, Sep.1993, pp. 1277-1294.
- [6] [Online] Available: <http://www.cancer.net/>
- [7] [Online] Available::<http://www.abta.org/>
- [8] V. Singh, "Textbook of Anatomy Head, Neck and Brain", vol.3, 2nd edition, 2014, Elsevier
- [9] D.Clark,N.Boutros and M.Mendez, "The Brain and Behavior An Introduction to Behavioral Neuroanatomy" 2nd edition, 2005, Cambridge University Press .
- [10] [Online] Available: <http://www.braintumor.org/>
- [11] Louis D.N., Ohgaki H., Wiestler O.D, Cavenee W.K. (Eds.), WHO Classification of Tumors of the Central Nervous System, International Agency for Research on Cancer (IARC), Lyon, France, 2007.
- [12] Cancer Support Community, "Frankly Speaking About Cancer: Brain Tumors", National Brain Tumor Society, New York, Final Rep. June 2013.
- [13] D. N. Louis, H. Ohgaki, O. D. Wiestler, W. K. Cavenee, P. C. Burger, A. Jouvett, B.W. Scheithauer, and P. Kleihues, "The 2007 who classification of tumours of the central nervous system, Acta Neuropathologica:, vol. 114, no. 2, 2007, pp. 97-109.
- [14][Online]Available: <http://www.oncologychannel.com/braincancer/>
- [15] R.A. Novelline and L.F. Squire, Squire's Fundamentals of Radiology, 2004 Harvard Univ Press, ISBN 0674012798

- [16] Y. Zhang, H. Qu and Y. Wang, "Adaptive Image Segmentation Based on Fast Thresholding and Image Merging", Artificial reality and Telexistence-Workshops, 1994, pp. 308-311.
- [17] T. Lindeberg and M.X. Li "Segmentation and classification of edges using minimum description length approximation and complementary junction cues", Computer Vision and Image Understanding, vol. 67, No. 1, 1997, pp. 88-98.
- [18] Bankman, I. N, "Handbook of Medical Image Processing and Analysis", 2nd edition 2008, Academic Press.
- [19] T. Lindeberg and M.X. Li "Segmentation and classification of edges using minimum description length approximation and complementary junction cues", Computer Vision and Image Understanding, Vol. 67, No. 1, 1997, pp. 88-98.
- [20] W.X. Kang, Q.Q. Yang and R.R. Liang, "The Comparative Research on Image Segmentation Algorithms", IEEE Conference on ETCS, 2009, pp. 703-707.
- [21] K.P. Wong, "Medical image segmentation: Methods and applications in functional imaging, in Handbook of Biomedical Image Analysis", Springer, 2005, pp. 111-182.
- [22] G. Mittelhaeusser and F. Kruggel, "Fast segmentation of brain magnetic resonance tomograms, in Computer Vision, Virtual Reality and Robotics in Medicine", Springer, 1995, pp. 237-241.
- [23] M. R. Kaus, S. K. Warfield, A. Nabavi, P. M. Black, F. A. Jolesz, and R. Kikinis, "Automated segmentation of MR images of brain tumors", Radiology, vol. 218, no. 2, 2001, pp. 586-591.
- [24] J. G. Park and C. Lee, "Skull stripping based on region growing for magnetic resonance brain images." Neuro Image, vol.47. issue 4, oct 2009, pp.1394-1407.
- [25] H. Zhang, J. E. Fritts, S. A. Goldman, "Image Segmentation Evaluation: A Survey of unsupervised methods", Computer vision and image understanding, 2008, pp. 260-280.
- [26] V. F. Chong, J.Y. Zhou, J. B. Khoo, J. Huang, and T.- K. Lim, "Tongue carcinoma: Tumor volume measurement", International Journal of Radiation Oncology Biology Physics, vol. 59, no. 1, 2004, pp. 59-66.
- [27] Y. Salman, M. Assal, A. Badawi, S. Alian, and M. E. El-Bayome, "Validation techniques for Quantitative Brain Tumors Measurements", Proceeding IEEE- Engineering in Medicine and Biology, Sep.2005, pp. 7048-7051.
- [28] M. Sato, S. Lakare, M. Wan, A. Kaufman, and M. Nakajima, "A gradient magnitude based region growing algorithm for accurate segmentation", IEEE, in Image Processing, 2000. Proceedings. 2000 International Conference on, Sep.2000, vol. 3, pp. 448-451.
- [29] S. Lakare and A. Kaufman, "3D segmentation techniques for medical volumes, Center for Visual Computing, Department of Computer Science, State University of New York, Dec.2000.
- [30] S. Lakare and A. Kaufman, 3D Segmentation Techniques for Medical Volumes, Center for Visual Computing, Department of Computer Science, State University of New York, Dec.2000.
- [31] W. Dou, S. Ruan, Y. Chen, D. Bloyet, and J.-M. Constans, "A framework of fuzzy information fusion for the segmentation of brain tumor tissues on MR images", Image and Vision Computing, vol. 25, no. 2, Feb.2007, pp. 164-171.
- [32] Y.-L Chang and X. Li, "Adaptive Image Region-Growing", IEEE Transaction on Image Processing, vol. 3, no. 6, Nov.1994, pp.868-872.
- [33] H. G. Kaganami and Z. Bei, "Region Based Detection versus Edge Detection", IEEE IHH-MSP, Sep. 2009, pp. 1217- 1221.
- [34] M. Letteboer, W. Niessen, P. Willems, E. B. Dam, and M. Viergever, "Interactive multi-scale watershed segmentation of tumors in MR brain images", in Proc. of the IMIVA Workshop of MICCAI, Citeseer, 2001.

- [35] E. Dam, M. Loog, and M. Letteboer, "Integrating automatic and interactive brain tumor segmentation, in Pattern Recognition", IEEE ICPR, Aug 2004. vol. 3, pp.790- 793.
- [36] S. Deorah, L.Charles, A. Zita and R. Timothy, "Trends in brain cancer incidence and survival in the United States: Surveillance", Epidemiology and End results program, 1973 to 2001", Neurosurgery Focus, 2006, vol.20, pp.1-7.
- [37] J. E. Cates, R. T. Whitaker, and G. M. Jones, "Case study:", vol. 9, no. 6, 2005, pp. 566-578.
- [38] A. Bleau and L. J. Leon, Watershed-based segmentation and region merging, Computer Vision and Image Understanding, vol. 77, no. 3, Mar.2000, pp. 317-370.
- [39]V.Gies and T. M. Bernard,"Statistical solution to watershed over-segmentation", IEEE ICIP, vol.3, Oct.2004, pp. 1863-1866.
- [40] J. Kong, J. Wang, Y. Lu, J. Zhang, Y. Li, and B. Zhang, "A novel approach for segmentation of MRI brain images", IEEE MELECON, May.2006, pp. 525-528.
- [41] T.U Paul and S.K. Bandyopadhyay, "Segmentation of Brain Tumor from Brain MRI Images Reintroducing K – Means with advanced Dual Localization Method", International Journal of Engineering Research and Applications, vol.2, Jun. 2012, pp.226-231.
- [42] J.C. Bezdek, "Pattern Recognition with Fuzzy Objective Function Algorithms", Kluwer Academics Publishers, 1981.
- [43] L. O. Hall, A. M. Bensaid, L. P. Clarke, R. P. Velthuizen, M. S. Silbiger, and J. C. Bezdek, "A comparison of neural network and fuzzy clustering techniques in segmenting magnetic resonance images of the brain", IEEE Transactions on Neural Networks, vol. 3, no. 5, Sep.1992, pp. 672-682.
- [44] L. Szilagyi, Z. Benyo, S. M. Szil'agyi, and H. Adam, "Mr brain image segmentation using an enhanced fuzzy c-means algorithm", IEEE Engineering in Medicine and Biology Society, vol. 1, Sep.2003, pp. 724-726.
- [45] W. Cai, S. Chen, and D. Zhang, "Fast and robust fuzzy c-means clustering algorithms incorporating local information for image segmentation", Pattern Recognition, vol. 40, no. 3, Mar. 2007, pp. 825-838.
- [46] T. Rohlfing, R. Brandt, R. Menzel, and C. R. Maurer, "Evaluation of atlas selection strategies for atlas-based image segmentation with application to confocal microscopy images of bee brains", Neuroimage, vol. 21, no. 4, Apr 2004, pp. 1428-1442.
- [47] T. Rohlfing, R. Brandt, R. Menzel, D. B. Russakoff, and C. R. M. Jr., "The Handbook of Biomedical Image Analysis", vol.III Registration Models, Quo Vadis, Atlas-Based Segmentation? 2005, Springer US, pp. 435-486.
- [48] A. F. Frangi, D. Rueckert, J. A. Schnabel, and W. J. Niessen,"Automatic construction of multiple-object three-dimensional statistical shape models: application to cardiac modeling", IEEE Transactions on Medical Imaging, vol. 21, no. 9, Sep.2002, pp. 1151-1166.
- [49] D. Perperidis, R. Mohiaddin, and D. Rueckert, "Construction of a 4D statistical atlas of the cardiac anatomy and its use in classification", MICCAI 2005, vol. 3750, 2005, pp. 402-410.
- [50] M. Lorenzo-Vald'es, G. I. Sanchez-Ortiz, R. Mohiaddin, and D. Rueckert, "Atlas-Based Segmentation and Tracking of 3D Cardiac MR Images Using Non-rigid Registration", MICCAI 2002,vol.2488,Oct 2002, pp. 642-650.
- [51] P. Fillard, X. Pennec, P. M. Thompson, and N. Ayache, "Evaluating Brain Anatomical Correlations via Canonical Correlation Analysis of Sulcal Lines", in Proc. of MICCAI'07 Workshop on Statistical Registration: Pair-wise and Group-wise Alignment and Atlas Formation, Brisbane, Australia, Dec. 2007.

- [52] S. Joshi, B. Davis, M. Jomier, and G. Gerig, "Unbiased diffeomorphic atlas construction for computational anatomy", *Neuroimage*, vol. 23 Suppl 1, 2004.
- [53] K. K. Bhatia, J. V. Hajnal, B. K. Puri, A. D. Edwards, and D. Rueckert, "Consistent groupwise non-rigid registration for atlas construction", *IEEE Symposium on Biomedical Imaging (ISBI)*, vol.1, Apr. 2004, pp. 908-911.
- [54] P. Lorenzen, B. Davis, G. Gerig, E. Bullitt, and S. Joshi, "Multiclass posterior atlas formation via unbiased kullback-leibler template estimation", *MICCAI In LNCS*, vol.3216, 2004, pp. 95-102.
- [55] P. Lorenzen, M. Prastawa, B. Davis, G. Gerig, E. Bullitt, and S. Joshi, "Multi-Modal Image Set Registration and Atlas Formation", *Medical Image Analysis*, vol. 10, no. 3, Jun. 2006, pp. 440-451.
- [56] M. Bach Cuadra, C. Pollo, A. Bardera, O. Cuisenaire, J. Villemure, and J. Thiran, "Atlas-Based Segmentation of Pathological Brain MR Images", *IEEE ICIP*, vol. 1, Sep.2003, pp. 14-17.
- [57] D. Rueckert, A. F. Frangi, and J. A. Schnabel, "Automatic construction of 3-D statistical deformation models of the brain using nonrigid registration", *IEEE Trans Med Imaging*, vol. 22, no. 8, Aug. 2003, pp. 1014-1025.
- [58] D. C. V. Essen and H. A. Drury, "Structural and functional analyses of human cerebral cortex using a surface-based atlas", *Journal of Neuroscience*, vol. 17, no. 18, Sep. 1997 pp. 7079-7102.
- [59] C. Studholme and V. Cardenas, "A template free approach to volumetric spatial normalization of brain anatomy", *Pattern Recognition Letters*, vol. 25, no. 10, Jul. 2004 pp. 1191-1202.
- [60] A. W. Toga and P. M. Thompson, "The role of image registration in brain mapping," *Image and Vision Computing*, vol. 19, Jan. 2001. pp. 3- 24
- [61] R. O. Duda, P. E. Hart, and D. G. Stork, "Pattern Classification", 2nd edition, 2012|John Wiley & Sons.
- [62] C. M. Bishop, "Pattern Recognition and Machine Learning", vol.1, 2006, Springer New York.
- [63] S. Keerthi and E. Gilbert, "Convergence of a Generalized SMO Algorithm for SVM Classifier Design. *Machine Learning*", vol. 46, Jan.2002, pp.351-360.
- [64] E. Alpaydin, "Introduction to Machine Learning", 2004, MIT Press.
- [65] T. Hastie, R. Tibshirani, J. Friedman, and J. Franklin, "The elements of statistical learning: Data mining, inference and prediction", *The Mathematical Intelligencer*, vol. 27, no. 2, 2005, pp. 83-85.
- [66] O. Chapelle, B. Scholkopf, and A. Zien, ed., *Semi- Supervised Learning*, vol. 2. 2006, MIT Press Cambridge.
- [67] L. P. Clarke, R. P. Velthuizen, S. Phuphanich, J.D. Schellenberg, J. A. Arrington and M. Silbiger, "MRI: Stability of Three Supervised Segmentation Techniques", *Magnetic Resonance Imaging*, vol.11, 1993, pp. 95-106.
- [68] V. Vapnik, "Statistical Learning Theory", 1998, Wiley, New York.
- [69] V. Vapnik, "The Nature of Statistical Learning Theory", 1995, Springer, New York.
- [70] J. Zhou, K. Chan, V. Chong, and S. Krishnan, "Extraction of brain tumor from MR images using one-class support vector machine", *IEEE-EMBS 2005*, Jan. 2006, pp. 6411-6414.
- [71] H. Cai, R. Verma, Y. Ou, S.-K. Lee, E. R. Melhem, and C. Davatzikos, "Probabilistic Segmentation of Brain Tumors Based on Multi-Modality Magnetic Resonance Images", *IEEE ISBI*, 2007, pp. 600-603.

- [72] R. Verma, E. I. Zacharaki, Y. Ou, H. Cai, S. Chawla, S.-K. Lee, E. R. Melhem, R. Wolf, and C. Davatzikos, "Multiparametric tissue characterization of brain neoplasms and their recurrence using pattern classification of MR images", *Academic Radiology*, vol. 15, no. 8, 2008, pp. 966-977.
- [73] S. Ruan, S. Lebonvallet, A. Merabet, and J. Constans, "Tumor Segmentation from a Multispectral MRI Images by using Support Vector Machine Classification", *IEEE ISBI*, 2007. pp. 1236-1239.
- [74] S. Ruan, N. Zhang, Q. Liao, and Y. Zhu, "Image fusion for following-up brain tumor evolution", *IEEE ISBI*, 2011, pp. 281-284.
- [75] H.-E. Assemlal, D. Tschumperlé, L. Brun and K. Siddiqi, "Recent advances in diffusion MRI modeling: Angular and radial reconstruction", *Medical Image Analysis*, vol.15, 2011, pp.369-396.
- [76] A. Kharrat, K. Gasmi, M. B. Messaoud, N. Benamrani and M. Abid, "A hybrid Approach for Automatic classification of Brain MRI using Genetic Algorithm and Support Vector Machine", *Leonardo journal of sciences*, vol.9, issue-17, 2010, pp.71-82.
- [77] M. F. B. Othman, N. B. Abdullah and N. F. B. Kamal, "MRI brain classification using Support vector machine", *IEEE-ICMSAO*, Apr.2011, pp.1-4.
- [78] G. Farias, M. Santos and V. Lopez, "Brain Tumor Diagnosis with wavelets and Support Vector Machines", *IEEE- ISKE*, Nov.2008, pp. 1453-1459.
- [79] N. Abdullah, U.K. Ngah and S.A. Aziz, "Image Classification of brain MRI using Support Vector Machine", *IEEE- IST*, May. 2011, pp. 241-247.
- [80] D. Terzopoulos, "On matching deformable models to images", *Technical Report 60*, Schlumberger Palo Alto research, 1986. Reprinted in *Topical Meeting on Machine Vision*, *Technical Digest Series*, vol. 12, 1987, pp. 160-167.
- [81] M. Kass, A. Witkin, and D. Terzopoulos, "Snakes: Active Contour Models", *International Journal of Computer Vision*, vol. 1, no. 4, 1987, pp. 321-331.
- [82] D. Terzopoulos and K. Fleischer, "Deformable models", *The Visual Computer*, vol. 4, 1988, pp. 306-331.
- [83] D. Terzopoulos, A. Witkin, and M. Kass, "Constraints on deformable models: recovering 3D shape and nonrigid motion", *Artificial Intelligence*, vol. 36, no. 1, 1988, pp. 91- 123.
- [84] M. A. Fischler and R. A. Elschlager, "The representation and matching of pictorial structures", *IEEE Trans. on Computers*, vol. 22, no. 1, 1973, pp. 67-92.
- [85] B. Widrow, "The "rubber-mask" technique", *Pattern Recognition*, vol. 5, 1973, pp. 175-211.
- [86] U. Grenander, Y. Chow and D. M. Keenan, "Hands: A Pattern Theoretic Study of Biological Shapes", 1991, New York: Springer-Verlag.
- [87] M. I. Miller, G. E. Christensen, Y. Amit, and U. Grenander, "Mathematical textbook of deformable neuroanatomies", *Proc. National Academy of Science*, vol. 90, 1993, pp. 11944-11948.
- [88] C.S. Poon and M. Braun, "Image segmentation by a deformable contour model incorporating region analysis", *Phys. Med. Biol.*, vol. 42, 1997, pp. 1833-1841.
- [89] A. A. Amini, T. E. Weymouth, and R. C. Jain, "Using dynamic programming for solving variational problems in vision," *IEEE Trans. Patt. Anal. Mach. Intell.*, vol. 12, no. 9, 1990, pp. 855-867.
- [90] L. D. Cohen, "On active contour models and balloons", *CVGIP: Image Understanding*, vol. 53, no. 2, 1991, pp. 211-218.

- [91] T. McInerney and D. Terzopoulos, "A dynamic finite element surface model for segmentation and tracking in multidimensional medical images with application to cardiac 4D image analysis", *Journal of Computerized Medical Imaging and Graphics*, 1994, vol. 19, no. 1, pp. 69–83.
- [92] V.Caselles, F.Catte, T. Coll, and F. Dibos, "A geometric model for active contours", *Numerische Mathematik*, vol. 66, 1993, pp. 1–31.
- [93] R. Malladi, J. A. Sethian, and B. C. Vemuri, "Shape modeling with front propagation: a level set approach," *IEEE Trans. Pattern Analysis and Machine Intelligent*, vol. 17, no. 2, 1995, pp. 158– 175.
- [94] V. Caselles, R. Kimmel, and G. Sapiro, "Geodesic active contours", in *Proc. International Journal of Computer Vision*, 1995, pp. 694–699.
- [95] R. T. Whitaker, "Volumetric deformable models: active blobs", *Proc. SPIE 2359, Visualization in Biomedical Computing*, 1994, pp.122-134.
- [96] G. Sapiro and A. Tannenbaum, "Affine invariant scale-space", *International Journal of Computer Vision*, vol. 11, no. 1, 1993, pp. 25–44.
- [97] B. B. Kimia, A. R. Tannenbaum, and S. W. Zucker, "Shapes, shocks, and deformations I: the components of two-dimensional shape and the reaction-diffusion space", *International Journal of Computer Vision*, vol. 15, 1995, pp. 189–224.
- [98] R. Kimmel, A. Amir, and A. M. Bruckstein, "Finding shortest paths on surfaces using evel sets propagation," *IEEE Trans. Pattern Analysis Machine Intelligent*, vol. 17, no. 6, 1995, pp. 635–640.
- [99] L. Alvarez, F. Guichard, P. L. Lions, and J. M. Morel, "Axioms and fundamental equations of image processing", *Archive for Rational Mechanics and Analysis*, vol. 123, no. 3, 1993, pp. 199–257.
- [100] S. Osher and J. A. Sethian, "Fronts propagating with curvature-dependent speed: algorithms based on Hamilton-Jacobi formulations", *J. Computational Physics*, vol. 79, 1988, pp. 12–49.
- [101] J. A. Sethian, "Level Set Methods and Fast Marching Methods: Evolving Interfaces in Computational Geometry, Fluid Mechanics", *Computer Vision, and Material Science Cambridge*, 2nd edition, 1999, UK: Cambridge University Press.